

# Non-Fatal Strangulation Documentation Toolkit



International Association of Forensic Nurses  
[www.ForensicNurses.org](http://www.ForensicNurses.org)  
November 2016

---

# TABLE OF CONTENTS

Preface	i
Strangulation Task Force Members	1
Purpose	3
Section I – Non-Fatal Strangulation	
Strangulation Assessment, Documentation, and Evidence Collection Guidelines	4
Section II – Non-Fatal Strangulation Policy and Procedure	
Example Policy and Procedure	7
Section III – Clinical Evaluation and Documentation	
Non-Fatal Strangulation Clinical Evaluation	9
Non-Fatal Strangulation Descriptors for Examiners	11
Non-Fatal Strangulation Documentation Form	14
Section IV – Discharge Instructions	
Example Strangulation Discharge Instructions	21
Additional Resources	22
References	
References	23
Bibliography	
Comprehensive Bibliography	25

## PREFACE

In 1992, The International Association of Forensic Nurses (IAFN) was created by a group of nurses that recognized violence as a healthcare problem. Over the past two and a half decades much progress has been made as it relates to the care of our specialized patient population. Through this progress, knowledge has been gained and practice guidelines continue to evolve with the goal of continuous provision of safe and effective patient care.

In early 2015, the IAFN, the Board of Directors and a group of members recognized strangulation as a healthcare concern that needed practice guidance throughout the organization, and as a result, the Strangulation Task Force was created and was proven to be a group of hard working, dedicated individuals that are truly experts on strangulation. This group was tasked with establishing standards for the organization and developed what would be utilized as a toolkit for best practice provision.

The Strangulation Toolkit provides the forensic nurse with detailed guidance on assessment techniques, documentation, and evidence collection for this patient population. This toolkit also provides documents such as discharge instructions and sample policies that can be adjusted to best suit your institution and your forensic practice.

As a toolkit, it should be mentioned that the IAFN does not endorse any changes to these documents. Limitations of this toolkit include the lack of research available to guide our practice, making the need for additional research related to the management of the patient that has been strangled a high priority. Also, it should be mentioned that each clinician must refer to their own individual state practice acts when considering the implementation of any parts of this toolkit.

The Strangulation Toolkit is the first of its kind to be endorsed by the IAFN and will be a useful guide to improving and standardizing the care of patients that have been strangled. As a group, we will continue to strive to move our profession forward and improve practice internationally and this toolkit proves to keep us on this path.

## **STRANGULATION TASK FORCE MEMBERS**

Barbra Bachmeier, MSN, JD, NP-C (Chair)  
Nurse Practitioner/Forensic Nurse Examiner  
IU Health – Methodist Emergency Medicine and Trauma Center  
Indianapolis, IN

Khara Breeden, DNP, MS, RN, SANE-A, SANE-P, CA/CP-SANE  
Missouri City, TX

Teresa J. Devitt-Lynch, MSN, RN-BC, SANE-A, CFN, CMI-I, DACFEI  
United States Navy  
Navy Medicine Education and Training Command  
Joint Base-San Antonio, Fort Sam Houston, TX

Ruth Downing, MSN, RN, CNP, SANE-A  
President and Founder  
Forensic Healthcare Consulting  
Delaware, OH

Diana Faugno, MSN, RN, CPN, SANE-A, SANE-P, FAAFS, DF-IAFN  
Eisenhower Medical Center  
Rancho Mirage, CA

Sarah Hines, BSN, RN, CFN, SANE-A  
Eskenazi Health Center of Hope  
Indianapolis, IN

Annie Lewis-O'Connor, PhD, MPH, NP-BC, FAAN  
Senior Nurse Scientist Founder and Director  
C.A.R.E. Clinic  
Brigham and Women's Hospital  
Boston, MA

Jenifer Markowitz, ND, RN, WHNP-BC, SANE-A, DF-IAFN  
Alexandria, VA

Jennifer Pierce-Weeks, RN, SANE-A, SANE-P  
Education Director  
International Association of Forensic Nurses  
Elkridge, MD

Linda Reimer, BScN, RN, SANE-A, TITC-CT  
Domestic Abuse and Sexual Assault Care Centre of York Region  
Mackenzie Richmond Hill Hospital  
Richmond Hill, ON

Holly Renz, RN, SANE-A, SANE-P  
Program Director  
Madison County SATC of Community Hospital  
Anderson, IN

Suzanne Rotolo, PhD, MSN, RN, SANE-A, SANE-P, CFN, FACFEI  
Dr. Rotolo Consulting  
Leesburg, VA

Bill Smock, MS, MD  
Police Surgeon  
Louisville Metro Police Department  
Clinical Professor of Emergency Medicine  
University of Louisville School of Medicine  
Louisville, KY

Gael Strack, Esq.  
CEO and Co-Founder  
Training Institute on Strangulation Prevention, a program of Alliance for HOPE International  
San Diego, CA

Sally Sturgeon DNP, RN, SANE-A, AFN-BC  
Forensic Nurse Examiner  
Institute of Clinical Forensic Medicine and Nursing  
Louisville, Kentucky

Melissa Vesperman, BSN, RN, SANE-A  
Forensic Nurse Coordinator  
St. Croix Valley SART  
River Falls, WI

Sarah Wells, BSN, RN, SANE-A, SANE-P  
Bon Secours Richmond Health System  
Bon Secours Richmond Forensic Nursing Services  
Richmond, VA

## **PURPOSE**

The Non-Fatal Strangulation Documentation Toolkit was developed by consensus to assist clinicians in multiple settings and various disciplines with the evaluation of non-fatal strangulation.

# STRANGULATION ASSESSMENT, DOCUMENTATION, AND EVIDENCE COLLECTION GUIDELINES

## Equipment Needed

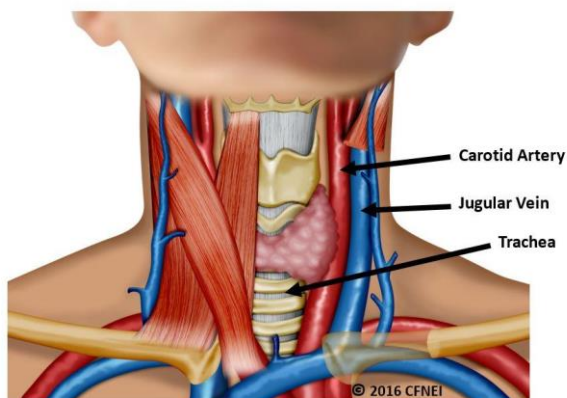
- Camera
- Measuring tape
- Evidence collection kit (swabs, sterile saline or water, envelopes, paper bags, evidence tape, etc.)
- ABFO No. 2 ruler
- Speculum
- Mannequin or Styrofoam head (optional)
- Gloves

## Definition

Strangulation is a form of asphyxia produced by a constant application of pressure to the neck. The three forms of strangulation are: hanging, ligature, and manual. Hanging occurs when a person is suspended with a ligature around his or her neck, which constricts due to the gravitational pull of the person's own body weight. Ligature strangulation occurs when the pressure applied around the neck is with a ligature only. Manual strangulation occurs when pressure is applied to the neck with hands, arms, or legs. (Ernoehazy, 2016; Funk & Schuppel, 2003; Line, Stanley, & Choi, 1985; Taliaferro, Hawley, McClane, & Strack, 2009; Wilbur et al., 2001).

## Anatomy/Pathophysiology

Pressure around the neck can result in the closure of blood vessels and/or air passages. Injury and death from strangulation occur from one or more mechanisms. The first mechanism is venous obstruction, whereby occlusion of the jugular veins results in congestion of the blood vessels and increased venous and intracranial pressure. The second mechanism is carotid artery obstruction, which stops blood flow and impedes oxygen delivery to the brain. The third mechanism is pressure on the carotid sinus that can cause acute bradycardia and/or cardiac arrest. Strangulation can result in injuries to the soft tissues of the neck, esophagus, larynx, trachea, cervical spine, and the laryngeal and facial nerves. (Hawley, McClane, & Strack, 2001; Shields, Corey, Weakley-Jones, & Stewart, 2010; Smith, Mills, & Taliaferro, 2001; Taliaferro, Hawley, McClane, & Strack, 2009).



© 2016 CFNEI. All rights reserved. May not be reproduced, published, distributed, displayed, performed, copied, or stored for public or private use without the written permission of CFNEI.

### **History/Patient Description of the Strangulation Event**

Describe what happened, using the patient's own words. Place quotation marks around the patient's comments. Also, describe the patient's appearance, behavior, speech, eye contact, and affect/demeanor using terms such as "slumped," "weeping," "averting eye contact," "stammering," "somber," "agitated," etc. Include the assailant's name, date of birth, and his or her relationship to the patient. Attach additional pages, if needed. Below are specific questions to ask each patient who reports strangulation. (As needed, reword questions to the appropriate developmental level of the patient.)

- Describe and demonstrate on the head model how you were strangled. One hand? Two hands? Arm? Leg? Other object(s)?
- How many times were you strangled?/Over what period of time?
- Were you shaken while you were being strangled?
- Was your head pounded on the ground or wall while you were being strangled?
- Did your feet leave the ground while you were being strangled?
- How long did the strangulation(s) last?
- On a scale of 0–10, how much pressure was applied to your neck during the strangulation(s)?
- What did you think was going to happen?
- What did the assailant say to you before, during, and after you were strangled?
- What made the person stop strangling you?
- Were you suffocated (defined as smothered)? (Suffocation refers to obstruction of the airway at the nose or mouth.)
- Did you have any difficulty breathing or an inability to breathe?
- Did you or do you currently have a cough?
- Did you or do you currently have trouble swallowing?
- Did you have a hoarse, raspy, or complete loss of voice?
- Did you or do you currently have any changes in your vision? (seeing spots, tunnel vision, blurry vision, everything went black, etc.)
- Did you or do you currently have any changes in your hearing? (roaring, ringing, etc.)
- Did you become dizzy or lightheaded?
- Did you lose consciousness? (passed out, blacked out, etc.)
- Did you experience any mental status changes? (restlessness, combativeness, amnesia, psychosis, etc.)
- Did you vomit as a result of being strangled?
- Did you lose control of urine or stool while you were being strangled?
- Were you sexually assaulted?
- Were you slapped, punched, kicked, or bitten anywhere on your body?
- Have you been strangled prior to this event?/How many times?
- Did you or do you have a headache?
- Did you bite your tongue or the inside of your mouth?
- If pregnant, are you having any abdominal cramping, vaginal discharge, or bleeding?
- Were you sexually assaulted during the event?

(Funk & Schuppel, 2003; Gwinn & Strack, 2013; Strack & McClane, 1999).

### **Documentation of Physical Findings/Description of Injuries**

Examine the head, face, neck, and chest completely, using 360 degrees. Closely examine the sclera, conjunctiva, lips, oral cavity, palate, ears, and scalp. Observe for areas of erythema, abrasion, contusion, swelling, laceration, incised wound(s), fracture, bite mark(s), burn(s), or tenderness. Record each injury, including patient statements about the injury (e.g. "he grabbed my neck; that wasn't there before he did that") by drawing a diagram. Label each injury drawn on the diagram by using the consecutive alphabetical or numerical systems (A, B, C or 1, 2, 3, etc.) to describe each injury separately. Attach additional pages if needed. Document the location, shape, color, and size of all injuries, using centimeters as the unit of measure. Note length, width, and depth for each injury (if possible). Also, measure the neck with a measuring tape to establish a baseline for follow-up measurements (to determine whether neck swelling is present). Include the following in the patient's assessment:

- Voice changes: Dysphonia (defined as hoarseness) or aphonia (defined as severe or complete loss of voice)



- Swallowing changes and tongue swelling: Dysphagia (defined as difficulty swallowing) or odynophagia (defined as painful swallowing)
- Breathing changes: Dyspnea (defined as difficulty breathing)
- Visible injuries on the neck and mastoid: Ligature marks/edema/abrasions (scratches and scrapes)/erythema/contusions
- Petechiae: Eyelids/peri-orbital region/face/scalp/neck/ears/soft palate/under tongue
- Subconjunctival/Scleral hemorrhage/Scleral edema (eyes)
- Neurological findings: Ptosis/facial droop/unilateral weakness/loss of sensation/paralysis/seizure
- Neck swelling: Measurement (in centimeters) for size (mark neck with a Sharpie pen for accurate follow-up measurement)
- Miscarriage/Pregnancy - FHT/LMP
- Lung injuries: Aspiration pneumonia/pulmonary edema
- Other symptoms: Acid reflux, etc.
- Pain, swelling, erythema, contusion, abrasion, petechiae, bite marks, knife wounds, or gunshot wounds on any other area of the body (i.e., chest, back, upper extremities, lower extremities)

(Christe et al., 2009; Faugno, Waszak, Strack, Brooks, & Gwinn, 2013; Funk & Schuppel, 2003; Gwinn & Strack, 2013; Hawley, McClane, & Strack, 2001; Strack & McClane, 1999; Taliaferro, Hawley, McClane, & Strack, 2009).

### Photographs

Use your facility/community protocol. If no protocol is available, use the guidelines listed below.

- Take full-body distant and mid-distance photographs. Take multiple photographs of the front, sides, and back of the face, neck, upper chest, and shoulders.
- Carefully assess and photograph the eyes and mouth. Take multiple photographs of both eyes of the patient looking up, down, to the left, to the right, and straight ahead. To visualize and photograph the conjunctival sac, gently pull down on the lower lid with a gloved hand. If no ocular trauma is present and if the patient is able to tolerate, flip the upper eyelids up on each eye to visualize and photograph.
- With the patient's mouth open, depress the tongue with appropriate assistive devices to light the internal structures. Take photographs of the upper and lower lips, frenula, under the tongue, the soft palate, uvula, and oropharynx. To completely visualize and photograph the oral structures, rotate the camera so the flash is in various positions, including the upright position, left, right, and upside down.
- Perform a complete head-to-toe assessment of the patient, and photograph and document all injuries. Take close-up photographs of all injuries with and without a measurement ruler in place. Ensure that the plane of the object being photographed is at 90 degrees.
- (Optional) Photograph the patient's demonstration on the strangulation model of how he or she was strangled.
- Take follow-up photographs of all visible injuries within 72 hours post-assault (based upon patient needs, availability, etc.).

(Funk & Schuppel, 2003; Paluch, 2013; Strack & McClane, 1999).

### Collection of Evidence

Use your facility/community protocol. Consult your local forensic laboratory for recommendations. If no protocol is available, use the guidelines listed below.

- Collect dried and moist secretions (i.e., blood stains, saliva, etc.) from the face, head, neck, and mouth. Use two or four (as indicated by protocol/recommendation) sterile cotton swabs for each specimen. Swab moist secretions with dry swabs. Swab dry secretions with swabs moistened with sterile saline or sterile water. Air dry the swabs before packaging in an envelope or a swab box.
- Make control swabs by moistening swabs with the sterile saline or sterile water used (as indicated by protocol/recommendation). If collecting control swabs, label, air dry, and package separately from the evidence samples.
- Collect fingernail swabs, if indicated per history. Place swabs from each hand into a separate, labeled envelope.
- Label each envelope or swab box with the contents, patient name, collector name, the date, and time of collection. Seal the envelope with tape, and then initial. Document location and the potential biological specimen identified.

(Gwinn & Strack, 2013; Hawley, McClane, & Strack, 2001).

## EXAMPLE POLICY AND PROCEDURE

### Policy Name: Standard of Practice in Non-Fatal Strangulation Cases

#### 1. Purpose

To have a policy that identifies and communicates evidenced-based best practice/standard of practice based upon the assessment of the patient, the caregiver/guardian/patient's consent, and medical status in non-fatal strangulation cases.

#### 2. Policy

Each patient will be assessed for the purpose of medical diagnoses and treatment. This will include the physical assessment, collection of potential biological and trace evidence to identify any forensic findings, and documentation of objective findings and subjective complaints (Faugno, Waszak, Strack, Brooks, & Gwinn, 2013).

Any procedure that is completed by another professional (i.e., social work, advocate) should be documented as such.

Follow institutional/local guidelines, policies, laws for the incapacitated patient or minor.

#### 3. Procedure

- a) Thorough head-to-toe physical assessment (genital examination to be conducted as indicated)
- b) Completion of danger assessment/lethality assessment (Campbell, 2004; Campbell, Webster, & Glass, 2009)
- c) Completion of strangulation documentation to include:
  - a. Written documentation form
  - b. Body mapping of injuries
  - c. Photo-documentation
  - d. Mannequin demonstration (optional)
- d) Neck circumference measurement
- e) Use of alternate light source (ALS)/ultraviolet (UV) light (as indicated or available) for identification of potential biological fluids and/or for enhancement of visual bruises (not to be used to identify bruises that cannot be seen) (Eldredge, Huggins, & Pugh, 2012)
- f) Potential evidence collection (as applicable or if indicated)
- g) Assist patient with acquiring the necessary resources to file for victim of violent crime fund/compensation per local jurisdiction (if available)
- h) Assess for safety planning/resources disposition  
Follow individual, local, mandated reporter for adult/pediatric population with referrals as needed to adult protection services (APS) and/or child protective services (CPS).
- i) If evaluation results indicate need, discuss possibility of observation or overnight admission.
- j) Discuss follow-up plan of care

#### 4. Follow-Up Care

Follow up examinations within 72 hours post assault. In case of holidays/weekends: follow up with a phone call within 72 hours, with a scheduled appointment as soon as possible (Taliaferro, Hawley, McClane, & Strack, 2009).

Follow-up appointment to consist of:

- a) Head-to-toe physical assessment
- b) Strangulation documentation form
- c) Photography (of progression of bruising or identification of new bruises)
- d) Neck circumference
- e) Use of ALS/UV light (as indicated or available) as indicated above in #3e
- f) Ongoing safety assessment

- g) Referrals to ear, nose, and throat (ENT) specialist, neurology, other providers, counseling per scope of practice

5. Terms

1. Strangulation: A form of asphyxia (lack of oxygen) characterized by closure of the blood vessels and/or air passages of the neck as a result of external pressure on the neck (Iserson, 1984; Line, Stanley, & Choi, 1985).
2. Standards of Practice. Authoritative statements that “[describe a competent level of nursing care as demonstrated by the nursing process” (ANA, 2010, p. 67).
3. Danger assessment: An easy and effective method for forensic nurses and other community professionals to identify those who are at the highest potential for being seriously injured or killed (lethality) by their intimate partners so as to immediately connect these patients and clients to a domestic violence service provider in their area.
4. ALS (alternate light source): A high-intensity light using differing wavelengths that may fluoresce fluids/fibers and help enhance bruises that can be seen under white light.
5. UV (ultraviolet) light: An electromagnetic radiation with a wavelength from 100 nm to 400 nm. A portion of the light spectrum, which is not visible to the naked eye, that may help fluoresce fluids/fibers.
6. Mannequin head: An effective tool to aid the patient in demonstrating the act of strangulation.

# NON-FATAL STRANGULATION CLINICAL EVALUATION

*The following content is recommended as components of the clinical evaluation.*

## Medical History

- Primary care physician
- Allergies
- Medical/Surgical history
- Pregnancy - LMP, live births, miscarriages, abortions
- Prior hospitalizations
- Smoking/Alcohol/Drug use
- Medications, including supplements/herbs

## Social History

- Employed
- Lives with
- Children (biological patient/suspect)
- Past history of sexual or physical abuse, domestic violence

## Review of Systems

### Physical Examination

- Appearance
- Eye contact
- Speech
- Responsiveness to clinician
- Nonverbal/Oral expression
- Facial expression
- Body posture and/or muscular tension
- Behaviors and actions
- Appearance of clothing
- Subjective complaints
- Any pain/Bleeding before, during, or after event
- Pre-existing complaints of pain, injury, or skin conditions

### Forensic Medical Photography - Digital and/or colposcope (with and without ruler/scale)

- Full body
- Close-up
- Face
- Head/Scalp
- Neck
- Chest
- Mouth
- Eyes
- Mannequin demonstration
- Other injuries (i.e., defensive)

## Danger Assessment

### Medical Evaluation/Radiology Studies (as indicated by medical provider)

- Pulse oximetry
- Chest X-ray
- Soft tissue of the neck X-ray
- CT of the neck with and/or without contrast
- CT angiogram of carotid/vertebral arteries
- MRI of the neck

- MRA of the neck
- MRI/MRA of the brain

# NON-FATAL STRANGULATION DESCRIPTORS FOR EXAMINERS

Donna A. Gaffney, DNSc, RN, FAAN

### Behaviors, Mannerisms, Speech, and Eye Contact

Do not use language that could be construed as evaluative or can be interpreted as a value statement, or words that assign a subjective or emotional experience to the survivor. Instead, use words that accurately **describe outward appearance, visible behavior, speech, and eye contact**. These are words that convey the emotional state of the survivor without specifically labeling it as such.

### Quantifying and Qualifying Behaviors (time, intensity, manner)

- When quantifying time, indicate the number of times a behavior was observed or the length of time it was observed (i.e., cried for 20 minutes)
- When qualifying time, name the event that coincided or preceded the behavior ( i.e., sobbed as she took off her clothes)
- When qualifying intensity, describe what was sensed (i.e., soft, loud, piercing, shrill, high-pitched, sharp, etc.)
- When qualifying manner, describe what was observed (i.e., measured, haltingly, abruptly, tentatively, etc.)

Always use the patient’s statements and place in quotation marks. Do not paraphrase.

Eye Contact or Visual Contact	Suggestions	Suggestions	Suggestions	Avoid
	Gape	Stare	Looks at (floor, ceiling, etc.)	Good
	Watch	Fixed	Only when addressed	Poor
	Avoid (when)	Avert	Closes eyes (when, how long)	“Good” and “poor” mean different things to different people
	Glance	Glare		

Speech	Suggestions	Suggestions	Suggestions	Avoid
	Mumble	Stammer	Responds in one or two word answers	
	Murmur	Stutter	Responds only when asked questions	
	Shout	Slow	Whispers (differentiate from hoarseness)	
	Scream	Cries while speaking	Hoarse (clarify if this is normal or new)	
			Hesitates (duration in seconds, minutes)	

<b>Responsive-ness to Clinician</b>	<b>Suggestions</b>	<b>Suggestions</b>	<b>Suggestions</b>	<b>Avoid</b>
	Follow directions (how)	Pause (before stating...)	Answers questions when asked	Cooperative
		Unresponsive	Responds only when asked questions	

<b>Nonverbal/ Oral Expression</b>	<b>Suggestions</b>	<b>Suggestions</b>	<b>Suggestions</b>	<b>Avoid</b>
	Cry	Sniffle	Wail	
	Moan	Sob	Whimper	
	Weep	Sigh		

<b>Facial Expressions</b>	<b>Suggestions</b>	<b>Suggestions</b>	<b>Suggestions</b>	<b>Avoid</b>
	Frown	Flinch	Pursed lips	
	Glower	Wince	Pucker	
	Scowl	Clenched jaw	Grinding teeth	
	Grimace	Biting lips		

<b>Body Posture and/or Muscular Tension</b>	<b>Suggestions</b>	<b>Suggestions</b>	<b>Suggestions</b>	<b>Avoid</b>
	Slouch	Stoop	Shudders	
	Tremor	Slump	Clenches fists	
	Quiver	Restless	Crosses arms in front of body	
	Tremble	Shake	Wrings hands	
	Clutching (what)	Feet pulled up as sits in chair	Draws legs up, wraps arms around knees (how and where)	

<b>Behaviors and Actions</b>	<b>Suggestions</b>	<b>Suggestions</b>	<b>Suggestions</b>	<b>Avoid</b>
	Pacing	Pulling at sheets	Holds front of shirt together with both hands	Afraid Fearful Scared
	Blew nose	Clutching clothes	Wipes at eyes with tissue	
	Startled	Stunned	Cowers	
	Cringe	Flinch		

Demeanor	Suggestions	Suggestions	Suggestions	Avoid
	Serious	Silent	Solemn	Depressed Sad
	Somber	Listless	Sluggish	In shock Cool Composed
	Quiet	Agitated	Irritated	Controlled Flat affect Indifferent
				Disinterested Angry Raging

### Describing Anxiety

State that the client is anxious and then support with observable behaviors: wringing hands, tapping feet, sweating profusely, dilated pupils, or the client's statement (e.g., "I feel nauseated," "I have a knot in my stomach," etc.).

2001, Donna Gaffney Associates



# NON-FATAL STRANGULATION DOCUMENTATION FORM

Patient Name: \_\_\_\_\_

Date: \_\_\_\_\_

Medical Record Number: \_\_\_\_\_

Time: \_\_\_\_\_

Strangulation is a serious event that often occurs in the context of intimate partner violence (IPV). Many times strangulation presents **NO VISIBLE INJURIES**. It is important to ask about strangulation in all IPV cases, and document positive disclosure or any signs and symptoms.

## Strangulation Event History

How long did the strangulation last? \_\_\_\_ seconds \_\_\_\_ minutes \_\_\_\_ cannot recall

How many times did strangulation occur? \_\_\_\_

Why/how did the strangulation stop? \_\_\_\_\_

What type of strangulation occurred? (Check all that apply)

Hanging      Ligature      Manual      Other

What was used to strangle the patient?

Right hand    Left hand    Both hands    Unknown    Chokehold maneuver

Other (describe) \_\_\_\_\_

Was the patient smothered?

No    Yes (describe) \_\_\_\_\_

Was the patient shaken during the incident?

No    Yes (describe) \_\_\_\_\_

Was the patient's head pounded against any object during the incident?

No    Yes (describe) \_\_\_\_\_

Was the patient slapped, kicked, or bitten anywhere?

No    Yes (describe) \_\_\_\_\_

Was the assailant wearing any jewelry on hands or wrists?

Unknown    No    Yes (describe) \_\_\_\_\_

Describe the neck pressure during strangulation on a 0-10 scale (0=no pressure and 10=crushing pressure):

\_\_\_\_\_

What is the measurement of the patient's neck circumference? \_\_\_\_\_

Was the patient sexually assaulted?

No      Yes

What was the patient thinking during the strangulation?

\_\_\_\_\_

What did the assailant say before, during, or after the strangulation?

\_\_\_\_\_

Describe mannequin demonstration (where applicable)

\_\_\_\_\_

### Signs/Symptoms of Strangulation

The following signs/symptoms should be asked about, assessed for and documented in writing, with body mapping, and by photo-imaging (if applicable). **Check ALL that apply.**

Signs	Prior to Strangulation	During Strangulation	After Strangulation	At time of Assessment
<b>Face</b>	<input type="checkbox"/> Red, flushed <input type="checkbox"/> Petechiae <input type="checkbox"/> Abrasions <input type="checkbox"/> Cuts <input type="checkbox"/> Lacerations <input type="checkbox"/> Discoloration <input type="checkbox"/> Swelling <input type="checkbox"/> Other _____	<input type="checkbox"/> Red, flushed <input type="checkbox"/> Petechiae <input type="checkbox"/> Abrasions <input type="checkbox"/> Cuts <input type="checkbox"/> Lacerations <input type="checkbox"/> Discoloration <input type="checkbox"/> Swelling <input type="checkbox"/> Other _____	<input type="checkbox"/> Red, flushed <input type="checkbox"/> Petechiae <input type="checkbox"/> Abrasions <input type="checkbox"/> Cuts <input type="checkbox"/> Lacerations <input type="checkbox"/> Discoloration <input type="checkbox"/> Swelling <input type="checkbox"/> Other _____	<input type="checkbox"/> Red, flushed <input type="checkbox"/> Petechiae <input type="checkbox"/> Abrasions <input type="checkbox"/> Cuts <input type="checkbox"/> Lacerations <input type="checkbox"/> Discoloration <input type="checkbox"/> Swelling <input type="checkbox"/> Other _____
<b>Eyes</b>	<input type="checkbox"/> Discoloration <input type="checkbox"/> Swelling <input type="checkbox"/> Abrasions <input type="checkbox"/> Petechiae: <b>Conjunctiva</b> <input type="checkbox"/> <i>Right</i> <input type="checkbox"/> <i>Left</i> <b>Eyelids</b> <input type="checkbox"/> <i>Upper right</i> <input type="checkbox"/> <i>Lower right</i> <input type="checkbox"/> <i>Upper left</i> <input type="checkbox"/> <i>Lower left</i>  <input type="checkbox"/> Subconjunctival hemorrhage <input type="checkbox"/> <i>Right</i> <input type="checkbox"/> <i>Left</i>  <input type="checkbox"/> Ptosis <input type="checkbox"/> <i>Right</i> <input type="checkbox"/> <i>Left</i>  <input type="checkbox"/> Vascular congestion <input type="checkbox"/> <i>Right</i> <input type="checkbox"/> <i>Left</i>  <input type="checkbox"/> Other _____	<input type="checkbox"/> Discoloration <input type="checkbox"/> Swelling <input type="checkbox"/> Abrasions <input type="checkbox"/> Petechiae: <b>Conjunctiva</b> <input type="checkbox"/> <i>Right</i> <input type="checkbox"/> <i>Left</i> <b>Eyelids</b> <input type="checkbox"/> <i>Upper right</i> <input type="checkbox"/> <i>Lower right</i> <input type="checkbox"/> <i>Upper left</i> <input type="checkbox"/> <i>Lower left</i>  <input type="checkbox"/> Subconjunctival hemorrhage <input type="checkbox"/> <i>Right</i> <input type="checkbox"/> <i>Left</i>  <input type="checkbox"/> Ptosis <input type="checkbox"/> <i>Right</i> <input type="checkbox"/> <i>Left</i>  <input type="checkbox"/> Vascular congestion <input type="checkbox"/> <i>Right</i> <input type="checkbox"/> <i>Left</i>  <input type="checkbox"/> Other _____	<input type="checkbox"/> Discoloration <input type="checkbox"/> Swelling <input type="checkbox"/> Abrasions <input type="checkbox"/> Petechiae: <b>Conjunctiva</b> <input type="checkbox"/> <i>Right</i> <input type="checkbox"/> <i>Left</i> <b>Eyelids</b> <input type="checkbox"/> <i>Upper right</i> <input type="checkbox"/> <i>Lower right</i> <input type="checkbox"/> <i>Upper left</i> <input type="checkbox"/> <i>Lower left</i>  <input type="checkbox"/> Subconjunctival hemorrhage <input type="checkbox"/> <i>Right</i> <input type="checkbox"/> <i>Left</i>  <input type="checkbox"/> Ptosis <input type="checkbox"/> <i>Right</i> <input type="checkbox"/> <i>Left</i>  <input type="checkbox"/> Vascular congestion <input type="checkbox"/> <i>Right</i> <input type="checkbox"/> <i>Left</i>  <input type="checkbox"/> Other _____	<input type="checkbox"/> Discoloration <input type="checkbox"/> Swelling <input type="checkbox"/> Abrasions <input type="checkbox"/> Petechiae: <b>Conjunctiva</b> <input type="checkbox"/> <i>Right</i> <input type="checkbox"/> <i>Left</i> <b>Eyelids</b> <input type="checkbox"/> <i>Upper right</i> <input type="checkbox"/> <i>Lower right</i> <input type="checkbox"/> <i>Upper left</i> <input type="checkbox"/> <i>Lower left</i>  <input type="checkbox"/> Subconjunctival hemorrhage <input type="checkbox"/> <i>Right</i> <input type="checkbox"/> <i>Left</i>  <input type="checkbox"/> Ptosis <input type="checkbox"/> <i>Right</i> <input type="checkbox"/> <i>Left</i>  <input type="checkbox"/> Vascular congestion <input type="checkbox"/> <i>Right</i> <input type="checkbox"/> <i>Left</i>  <input type="checkbox"/> Other _____
<b>Nose</b>	<input type="checkbox"/> Bleeding <input type="checkbox"/> Swelling <input type="checkbox"/> Petechiae <input type="checkbox"/> Discoloration <input type="checkbox"/> Other _____	<input type="checkbox"/> Bleeding <input type="checkbox"/> Swelling <input type="checkbox"/> Petechiae <input type="checkbox"/> Discoloration <input type="checkbox"/> Other _____	<input type="checkbox"/> Bleeding <input type="checkbox"/> Swelling <input type="checkbox"/> Petechiae <input type="checkbox"/> Discoloration <input type="checkbox"/> Other _____	<input type="checkbox"/> Bleeding <input type="checkbox"/> Swelling <input type="checkbox"/> Petechiae <input type="checkbox"/> Discoloration <input type="checkbox"/> Other _____

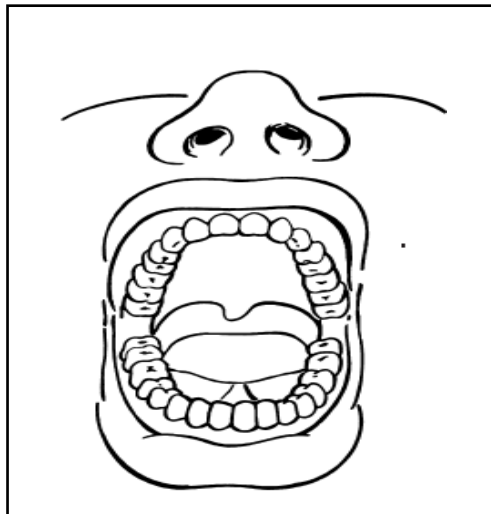
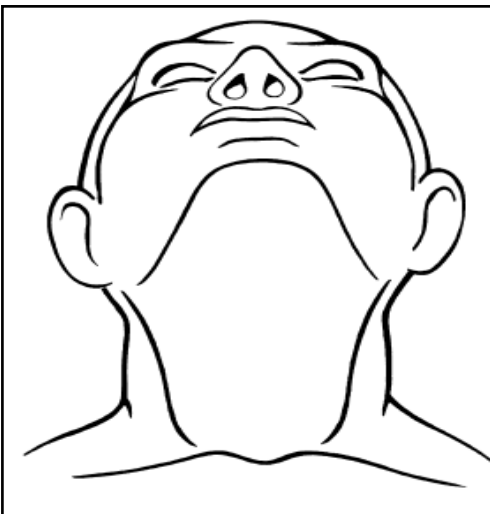
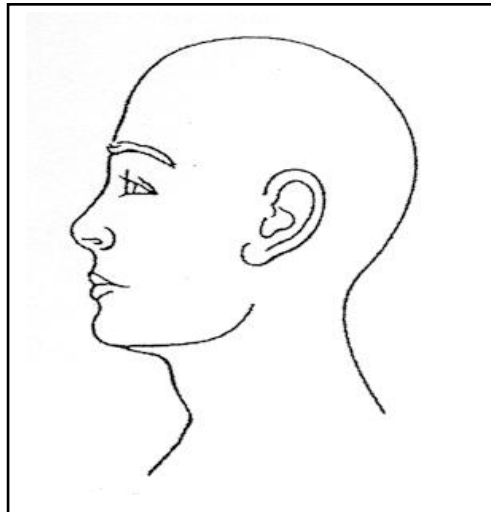
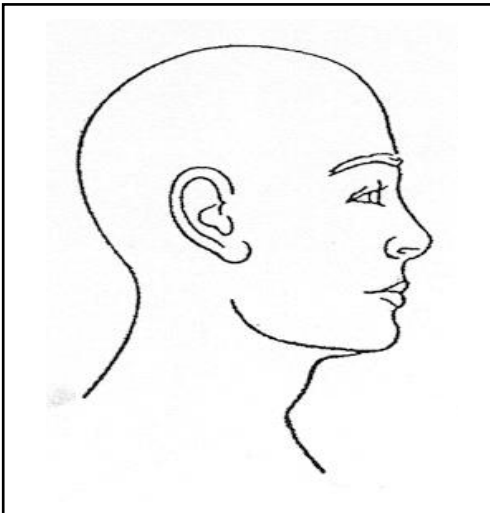
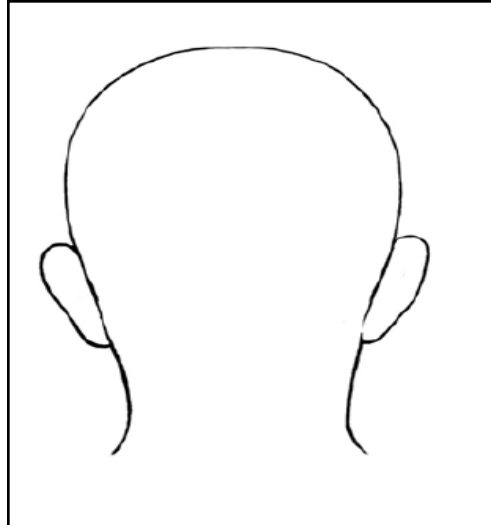
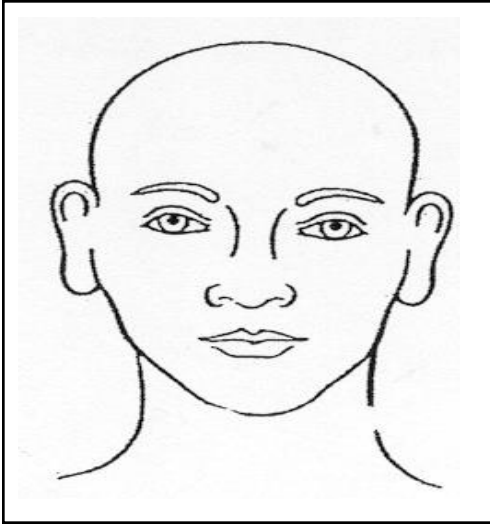
Signs	Prior to Strangulation	During Strangulation	After Strangulation	At time of Assessment
<b>Mouth</b>	<input type="checkbox"/> Discoloration <input type="checkbox"/> Swollen tongue <input type="checkbox"/> Swollen lips <input type="checkbox"/> Cut <input type="checkbox"/> Lacerations <input type="checkbox"/> Abrasions <input type="checkbox"/> Petechiae <input type="checkbox"/> Other	<input type="checkbox"/> Discoloration <input type="checkbox"/> Swollen tongue <input type="checkbox"/> Swollen lips <input type="checkbox"/> Cut <input type="checkbox"/> Lacerations <input type="checkbox"/> Abrasions <input type="checkbox"/> Petechiae <input type="checkbox"/> Other	<input type="checkbox"/> Discoloration <input type="checkbox"/> Swollen tongue <input type="checkbox"/> Swollen lips <input type="checkbox"/> Cut <input type="checkbox"/> Lacerations <input type="checkbox"/> Abrasions <input type="checkbox"/> Petechiae <input type="checkbox"/> Other	<input type="checkbox"/> Discoloration <input type="checkbox"/> Swollen tongue <input type="checkbox"/> Swollen lips <input type="checkbox"/> Cut <input type="checkbox"/> Lacerations <input type="checkbox"/> Abrasions <input type="checkbox"/> Petechiae <input type="checkbox"/> Other
<b>Ears</b>	<input type="checkbox"/> Petechiae <input type="checkbox"/> <i>Right</i> <input type="checkbox"/> <i>Left</i> <input type="checkbox"/> Bleeding from ear canal <input type="checkbox"/> <i>Right</i> <input type="checkbox"/> <i>Left</i> <input type="checkbox"/> Discoloration <input type="checkbox"/> Auditory changes <input type="checkbox"/> Other	<input type="checkbox"/> Petechiae <input type="checkbox"/> <i>Right</i> <input type="checkbox"/> <i>Left</i> <input type="checkbox"/> Bleeding from ear canal <input type="checkbox"/> <i>Right</i> <input type="checkbox"/> <i>Left</i> <input type="checkbox"/> Discoloration <input type="checkbox"/> Auditory changes <input type="checkbox"/> Other	<input type="checkbox"/> Petechiae <input type="checkbox"/> <i>Right</i> <input type="checkbox"/> <i>Left</i> <input type="checkbox"/> Bleeding from ear canal <input type="checkbox"/> <i>Right</i> <input type="checkbox"/> <i>Left</i> <input type="checkbox"/> Discoloration <input type="checkbox"/> Auditory changes <input type="checkbox"/> Other	<input type="checkbox"/> Petechiae <input type="checkbox"/> <i>Right</i> <input type="checkbox"/> <i>Left</i> <input type="checkbox"/> Bleeding from ear canal <input type="checkbox"/> <i>Right</i> <input type="checkbox"/> <i>Left</i> <input type="checkbox"/> Discoloration <input type="checkbox"/> Auditory changes <input type="checkbox"/> Other
<b>Head/scalp</b>	<input type="checkbox"/> Petechiae on scalp <input type="checkbox"/> Pulled hair <input type="checkbox"/> Contusions <input type="checkbox"/> Other	<input type="checkbox"/> Petechiae on scalp <input type="checkbox"/> Pulled hair <input type="checkbox"/> Contusions <input type="checkbox"/> Other	<input type="checkbox"/> Petechiae on scalp <input type="checkbox"/> Pulled hair <input type="checkbox"/> Contusions <input type="checkbox"/> Other	<input type="checkbox"/> Petechiae on scalp <input type="checkbox"/> Pulled hair <input type="checkbox"/> Contusions <input type="checkbox"/> Other
<b>Neck/under Chin</b>	<input type="checkbox"/> Redness <input type="checkbox"/> Scratch marks/abrasions <input type="checkbox"/> Bruises <input type="checkbox"/> Neck pain _____ (Pain scale 0-10) <input type="checkbox"/> Bruises <input type="checkbox"/> Swelling <input type="checkbox"/> Ligature marks <input type="checkbox"/> Subcutaneous emphysema <input type="checkbox"/> Other	<input type="checkbox"/> Redness <input type="checkbox"/> Scratch marks/abrasions <input type="checkbox"/> Bruises <input type="checkbox"/> Neck pain _____ (Pain scale 0-10) <input type="checkbox"/> Bruises <input type="checkbox"/> Swelling <input type="checkbox"/> Ligature marks <input type="checkbox"/> Subcutaneous emphysema <input type="checkbox"/> Other	<input type="checkbox"/> Redness <input type="checkbox"/> Scratch marks/abrasions <input type="checkbox"/> Bruises <input type="checkbox"/> Neck pain _____ (Pain scale 0-10) <input type="checkbox"/> Bruises <input type="checkbox"/> Swelling <input type="checkbox"/> Ligature marks <input type="checkbox"/> Subcutaneous emphysema <input type="checkbox"/> Other	<input type="checkbox"/> Redness <input type="checkbox"/> Scratch marks/abrasions <input type="checkbox"/> Bruises <input type="checkbox"/> Neck pain _____ (Pain scale 0-10) <input type="checkbox"/> Bruises <input type="checkbox"/> Swelling <input type="checkbox"/> Ligature marks <input type="checkbox"/> Subcutaneous emphysema <input type="checkbox"/> Other
<b>Shoulders</b>	<input type="checkbox"/> Redness <input type="checkbox"/> Scratch marks/abrasions <input type="checkbox"/> Bruises <input type="checkbox"/> Neck pain _____ (Pain scale 0-10) <input type="checkbox"/> Bruises <input type="checkbox"/> Other	<input type="checkbox"/> Redness <input type="checkbox"/> Scratch marks/abrasions <input type="checkbox"/> Bruises <input type="checkbox"/> Neck pain _____ (Pain scale 0-10) <input type="checkbox"/> Bruises <input type="checkbox"/> Other	<input type="checkbox"/> Redness <input type="checkbox"/> Scratch marks/abrasions <input type="checkbox"/> Bruises <input type="checkbox"/> Neck pain _____ (Pain scale 0-10) <input type="checkbox"/> Bruises <input type="checkbox"/> Other	<input type="checkbox"/> Redness <input type="checkbox"/> Scratch marks/abrasions <input type="checkbox"/> Bruises <input type="checkbox"/> Neck pain _____ (Pain scale 0-10) <input type="checkbox"/> Bruises <input type="checkbox"/> Other

Signs	Prior to Strangulation	During Strangulation	After Strangulation	At time of Assessment
<b>Chest</b>	<input type="checkbox"/> Redness <input type="checkbox"/> Scratch marks/abrasions <input type="checkbox"/> Bruises <input type="checkbox"/> Neck pain _____ <small>(Pain scale 0-10)</small> <input type="checkbox"/> Bruises <input type="checkbox"/> Swelling <input type="checkbox"/> Subcutaneous emphysema <input type="checkbox"/> Other _____	<input type="checkbox"/> Redness <input type="checkbox"/> Scratch marks/abrasions <input type="checkbox"/> Bruises <input type="checkbox"/> Neck pain _____ <small>(Pain scale 0-10)</small> <input type="checkbox"/> Bruises <input type="checkbox"/> Swelling <input type="checkbox"/> Subcutaneous emphysema <input type="checkbox"/> Other _____	<input type="checkbox"/> Redness <input type="checkbox"/> Scratch marks/abrasions <input type="checkbox"/> Bruises <input type="checkbox"/> Neck pain _____ <small>(Pain scale 0-10)</small> <input type="checkbox"/> Bruises <input type="checkbox"/> Swelling <input type="checkbox"/> Subcutaneous emphysema <input type="checkbox"/> Other _____	<input type="checkbox"/> Redness <input type="checkbox"/> Scratch marks/abrasions <input type="checkbox"/> Bruises <input type="checkbox"/> Neck pain _____ <small>(Pain scale 0-10)</small> <input type="checkbox"/> Bruises <input type="checkbox"/> Swelling <input type="checkbox"/> Subcutaneous emphysema <input type="checkbox"/> Other _____

Symptoms	Prior to Strangulation	During Strangulation	After Strangulation	At time of Assessment
<b>Behavioral</b>	<input type="checkbox"/> Agitation <input type="checkbox"/> Combative <input type="checkbox"/> Anxiety <input type="checkbox"/> Memory disruption <input type="checkbox"/> Confusion <input type="checkbox"/> Other _____	<input type="checkbox"/> Agitation <input type="checkbox"/> Combative <input type="checkbox"/> Anxiety <input type="checkbox"/> Memory disruption <input type="checkbox"/> Confusion <input type="checkbox"/> Other _____	<input type="checkbox"/> Agitation <input type="checkbox"/> Combative <input type="checkbox"/> Anxiety <input type="checkbox"/> Memory disruption <input type="checkbox"/> Confusion <input type="checkbox"/> Other _____	<input type="checkbox"/> Agitation <input type="checkbox"/> Combative <input type="checkbox"/> Anxiety <input type="checkbox"/> Memory disruption <input type="checkbox"/> Confusion <input type="checkbox"/> Other _____
<b>Neurological</b>	<input type="checkbox"/> LOC <input type="checkbox"/> Uncertain if LOC <input type="checkbox"/> Incontinence of urine <input type="checkbox"/> Incontinence of feces <input type="checkbox"/> Seizures <input type="checkbox"/> Headache _____ <small>(Pain scale 0-10)</small> <input type="checkbox"/> Dizzy <input type="checkbox"/> Fainting <input type="checkbox"/> Tinnitus <input type="checkbox"/> Visual changes <input type="checkbox"/> Other _____	<input type="checkbox"/> LOC <input type="checkbox"/> Uncertain if LOC <input type="checkbox"/> Incontinence of urine <input type="checkbox"/> Incontinence of feces <input type="checkbox"/> Seizures <input type="checkbox"/> Headache _____ <small>(Pain scale 0-10)</small> <input type="checkbox"/> Dizzy <input type="checkbox"/> Fainting <input type="checkbox"/> Tinnitus <input type="checkbox"/> Visual changes <input type="checkbox"/> Other _____	<input type="checkbox"/> LOC <input type="checkbox"/> Uncertain if LOC <input type="checkbox"/> Incontinence of urine <input type="checkbox"/> Incontinence of feces <input type="checkbox"/> Seizures <input type="checkbox"/> Headache _____ <small>(Pain scale 0-10)</small> <input type="checkbox"/> Dizzy <input type="checkbox"/> Fainting <input type="checkbox"/> Tinnitus <input type="checkbox"/> Visual changes <input type="checkbox"/> Other _____	<input type="checkbox"/> LOC <input type="checkbox"/> Uncertain if LOC <input type="checkbox"/> Incontinence of urine <input type="checkbox"/> Incontinence of feces <input type="checkbox"/> Seizures <input type="checkbox"/> Headache _____ <small>(Pain scale 0-10)</small> <input type="checkbox"/> Dizzy <input type="checkbox"/> Fainting <input type="checkbox"/> Tinnitus <input type="checkbox"/> Visual changes <input type="checkbox"/> Other _____
<b>Throat/Voice</b>	<input type="checkbox"/> Dysphagia <input type="checkbox"/> Odynophagia (pain) <input type="checkbox"/> Dysphasia <input type="checkbox"/> Aphasia <input type="checkbox"/> Drooling or Inability to swallow <input type="checkbox"/> Throat pain _____ <small>(Pain scale 0-10)</small> <input type="checkbox"/> Hoarse/Raspy <input type="checkbox"/> Other _____	<input type="checkbox"/> Dysphagia <input type="checkbox"/> Odynophagia (pain) <input type="checkbox"/> Dysphasia <input type="checkbox"/> Aphasia <input type="checkbox"/> Drooling or Inability to swallow <input type="checkbox"/> Throat pain _____ <small>(Pain scale 0-10)</small> <input type="checkbox"/> Hoarse/Raspy <input type="checkbox"/> Other _____	<input type="checkbox"/> Dysphagia <input type="checkbox"/> Odynophagia (pain) <input type="checkbox"/> Dysphasia <input type="checkbox"/> Aphasia <input type="checkbox"/> Drooling or Inability to swallow <input type="checkbox"/> Throat pain _____ <small>(Pain scale 0-10)</small> <input type="checkbox"/> Hoarse/Raspy <input type="checkbox"/> Other _____	<input type="checkbox"/> Dysphagia <input type="checkbox"/> Odynophagia (pain) <input type="checkbox"/> Dysphasia <input type="checkbox"/> Aphasia <input type="checkbox"/> Drooling or Inability to swallow <input type="checkbox"/> Throat pain _____ <small>(Pain scale 0-10)</small> <input type="checkbox"/> Hoarse/Raspy <input type="checkbox"/> Other _____

Symptoms	Prior to Strangulation	During Strangulation	After Strangulation	At time of Assessment
<b>Respiratory</b>	<input type="checkbox"/> Stridor <input type="checkbox"/> Coughing <input type="checkbox"/> Hyper-ventilation <input type="checkbox"/> Respiratory distress <input type="checkbox"/> Hemoptysis <input type="checkbox"/> Inability to tolerate supine position <input type="checkbox"/> Other _____ _____	<input type="checkbox"/> Stridor <input type="checkbox"/> Hoarseness <input type="checkbox"/> Hyper-ventilation <input type="checkbox"/> Respiratory distress <input type="checkbox"/> Hemoptysis <input type="checkbox"/> Inability to tolerate supine position <input type="checkbox"/> Other _____ _____	<input type="checkbox"/> Stridor <input type="checkbox"/> Hoarseness <input type="checkbox"/> Hyper-ventilation <input type="checkbox"/> Respiratory distress <input type="checkbox"/> Hemoptysis <input type="checkbox"/> Inability to tolerate supine position <input type="checkbox"/> Other _____ _____	<input type="checkbox"/> Stridor <input type="checkbox"/> Hoarseness <input type="checkbox"/> Hyper-ventilation <input type="checkbox"/> Respiratory distress <input type="checkbox"/> Hemoptysis <input type="checkbox"/> Inability to tolerate supine position <input type="checkbox"/> Other _____ _____
<b>Gynecological</b>	<input type="checkbox"/> Vaginal bleeding <input type="checkbox"/> Pregnant <input type="checkbox"/> Contractions <input type="checkbox"/> FHR _____ <input type="checkbox"/> Other _____ _____	<input type="checkbox"/> Vaginal bleeding <input type="checkbox"/> Pregnant <input type="checkbox"/> Contractions <input type="checkbox"/> FHR _____ <input type="checkbox"/> Other _____ _____	<input type="checkbox"/> Vaginal bleeding <input type="checkbox"/> Pregnant <input type="checkbox"/> Contractions <input type="checkbox"/> FHR _____ <input type="checkbox"/> Other _____ _____	<input type="checkbox"/> Vaginal bleeding <input type="checkbox"/> Pregnant <input type="checkbox"/> Contractions <input type="checkbox"/> FHR _____ <input type="checkbox"/> Other _____ _____ <input type="checkbox"/> EDC _____
<b>Genitourinary</b>	<input type="checkbox"/> Dysuria <input type="checkbox"/> Other _____	<input type="checkbox"/> Dysuria <input type="checkbox"/> Other _____	<input type="checkbox"/> Dysuria <input type="checkbox"/> Other _____	<input type="checkbox"/> Dysuria <input type="checkbox"/> Other _____
<b>Gastrointestinal</b>	<input type="checkbox"/> Nausea <input type="checkbox"/> Vomiting <input type="checkbox"/> Anal/rectal bleeding <input type="checkbox"/> Abdominal pain _____ <small>(scale 0-10)</small>	<input type="checkbox"/> Nausea <input type="checkbox"/> Vomiting <input type="checkbox"/> Anal/rectal bleeding <input type="checkbox"/> Abdominal pain _____ <small>(scale 0-10)</small>	<input type="checkbox"/> Nausea <input type="checkbox"/> Vomiting <input type="checkbox"/> Anal/rectal bleeding <input type="checkbox"/> Abdominal pain _____ <small>(scale 0-10)</small>	<input type="checkbox"/> Nausea <input type="checkbox"/> Vomiting <input type="checkbox"/> Anal/rectal bleeding <input type="checkbox"/> Abdominal pain _____ <small>(scale 0-10)</small>

Please indicate all injuries checked above on the body maps below.



Please indicate all injuries checked above on the body maps below.

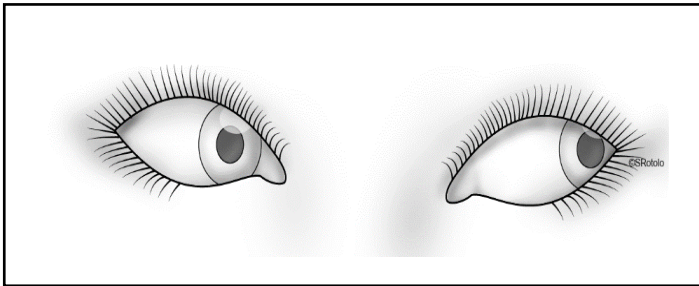
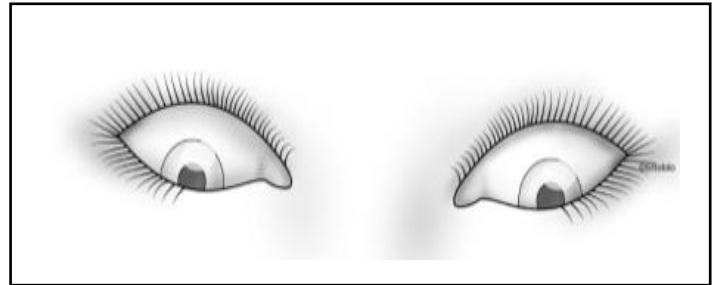
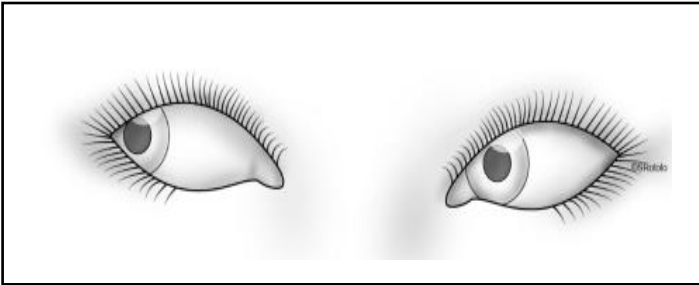
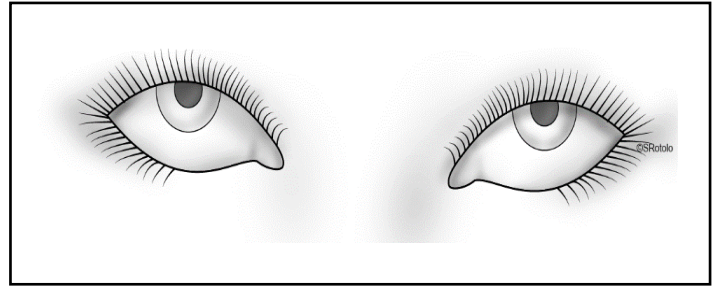
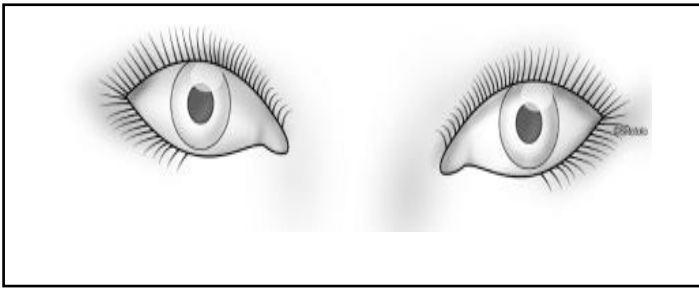


Photo-documentation of findings:  Yes  No

**Notes** \_\_\_\_\_  
\_\_\_\_\_  
\_\_\_\_\_  
\_\_\_\_\_  
\_\_\_\_\_  
\_\_\_\_\_  
\_\_\_\_\_  
\_\_\_\_\_

## EXAMPLE STRANGULATION DISCHARGE INSTRUCTIONS

Because you have reported being “choked” or strangled, we are providing you with the following instructions:

Make sure someone stays with you for the next 24–72 hours after this event.

**Health complications can appear immediately or may develop a few days after a strangulation event. Please call 911 or report immediately to the nearest emergency department if you notice any of the following:**

- Problems breathing, difficulty breathing while lying down, shortness of breath, persistent cough, or coughing up blood
- Loss of consciousness or “passing out”
- Changes in your voice or difficulty speaking
- Difficulty swallowing, a lump in your throat, or muscle spasms in your throat or neck
- Swelling to your throat, neck, or tongue
- Increasing neck pain
- Left- or right-sided weakness, numbness, or tingling
- Drooping eyelid
- Difficulty speaking or understanding speech
- Difficulty walking
- Headache not relieved by pain medication
- Dizziness, lightheadedness or changes in your vision
- Pinpoint red or purple dots on your face or neck, or burst blood vessels in your eye
- Seizures
- Behavioral changes, memory loss, or confusion
- Thoughts of harming yourself or others

**If you are pregnant**, report the strangulation and any of the following symptoms to your doctor immediately:

- Decreased movement of the baby
- Vaginal spotting or bleeding
- Abdominal pain
- Contractions

You may notice some bruising or mild discomfort. Apply ice to the sore areas for 20 minutes at a time, 4 times per day, for the first 2 days. If you notice new bruising or injury, follow up for additional photo-documentation.

After your initial evaluation, keep a list of any changes in symptoms to share with your healthcare provider and your law enforcement contact.

- It is important to have a follow-up medical screening in 1–2 weeks with your healthcare provider.
- A follow-up forensic examination is needed within 72 hours.

Please follow up with the crisis/advocacy center at \_\_\_\_\_ to clarify your options and discuss safety planning. If you have questions or concerns regarding your legal case, please contact the police department, officer involved, prosecutor, or victim advocate by calling \_\_\_\_\_.

Forensic Nurse: \_\_\_\_\_ Phone: \_\_\_\_\_



## ADDITIONAL RESOURCES

### General Resources

International Association of Forensic Nurses Position Statement [The Evaluation and Treatment of Non-Fatal Strangulation in the Health Care Setting](#) (October 2016)

Strangulation Training Institute [Recommendations for the Medical/Radiographic Evaluation of Acute Adult Non-Fatal Strangulation](#) (September 2016)

### Sample Documents from the Strangulation Toolkit

Non-Fatal Strangulation Clinical Evaluation ([Word](#)) ([PDF](#))

Non-Fatal Strangulation Descriptors for Examiners ([Word](#)) ([PDF](#))

Non-Fatal Strangulation Documentation Form ([Word](#)) ([PDF](#))

Example Strangulation Discharge Instructions ([Word](#)) ([PDF](#))

## REFERENCES

- American Nurses Association (ANA). (2010). *Nursing's social policy statement* (3rd ed.). Silver Spring, MD: Nursesbooks.org.
- Campbell, J. C. (2004). *Danger assessment*. Retrieved May 5, 2016, from <http://www.dangerassessment.org>
- Campbell, J. C., Webster, D. W., & Glass N. (2009). The danger assessment: Validation of a lethality risk assessment instrument for intimate partner femicide. *Journal of Interpersonal Violence, 24*(4), 653–674.
- Christe, A., Thoeny, H., Ross, S., Spendlove, D., Tshering, D., Bollinger, S., Grabherr, S., Thali, M. J., Vock, P., & Oesterhelweg, L. (2009). Life-threatening versus non-life-threatening manual strangulation: Are there appropriate criteria for MR imaging of the neck? *European Radiology, 19*(8), 1882–1889.
- Eldredge, K., Huggins, E., & Pugh, L. C. (2012). Alternate light sources in sexual assault examinations: An evidence-based practice project. *Journal of Forensic Nursing, 8*(1), 39–44.
- Ernoehazy, W., Jr. (2016, January 19). Hanging injuries and strangulation. *Medscape*. Retrieved May 5, 2016, from <http://emedicine.medscape.com/article/826704>
- Faugno, D., Waszak, D., Strack, G. B., Brooks, M. A., & Gwinn, C. G. (2013). Strangulation forensic examination best practice for health care providers. *Advanced Emergency Nursing Journal, 35*(4), 314–327.
- Funk, M., & Schuppel, J. (2003). Strangulation injuries. *WMJ: Official Publication of the State Medical Society of Wisconsin, 102*(3), 41–45.
- Gwinn, C., & Strack, G. B. (2012). *Welcome to train the trainer: Part 1 of training*. San Diego, CA: Training Institute on Strangulation Prevention.
- Hawley, D., McClane, G. E., & Strack, G. B. (2001). A review of 300 attempted strangulation cases. Part III: Injuries in fatal cases. *The Journal of Emergency Medicine, 21*(3), 317–322.
- Iserson, K. V. (1984). Strangulation: A review of ligature, manual, and postural neck compression injuries. *Annals of Emergency Medicine, 13*(3), 179–185.
- Line, W. S., Jr., Stanley, R. B., Jr., & Choi, J. C. (1985). Strangulation. A full spectrum of blunt neck trauma. *Annals of Otolaryngology, Rhinology, and Laryngology, 94*(6), 542–546.
- Paluch, M. (2013). Strangulation in domestic violence cases: Overcoming evidentiary challenges to reduce lethality. *Developments of New York State Family Law*.
- Shields, L. B., Corey, T. B., Weakley-Jones, B., & Stewart, D. (2010). Living victims of strangulation. A 10-year review of cases in a metropolitan community. *The American Journal of Forensic Medicine and Pathology, 31*(4), 320–325.
- Smith, D. J., Mills, T., & Taliaferro, E. H. (2001). Frequency and relationship of reported symptomology in victims of intimate partner violence. The effects of multiple strangulation attacks. *The Journal of Emergency Medicine, 21*(3), 323–329.

- Strack, G. B., & McClane, G. (1999). *How to improve your investigation and prosecution of strangulation cases* (2nd ed.). D. C. James (Ed.). San Diego, CA. Retrieved May 5, 2016, from [http://www.ncdsv.org/images/strangulation\\_article.pdf](http://www.ncdsv.org/images/strangulation_article.pdf)
- Taliaferro, E., Hawley, D., McClane, G., & Strack, G. (2009). Strangulation in intimate partner violence. In C. Mitchell & D. Anglin (Eds.), *Intimate partner violence: A health-based perspective* (pp. 217–236). New York, NY: Oxford University Press.
- Wilber, L., Higley, M., Hatfield, J., Surprenant, Z., Taliaferro, E., Smith, D. J., & Paolo, A. (2001). Survey results of women who have been strangled while in an abusive relationship. *The Journal of Emergency Medicine*, 21(3), 297–302.

## COMPREHENSIVE BIBLIOGRAPHY

- Abrahams, N., Jewkes, R., Martin, L. J., Mathews, S., Vetten, L., & Lombard, C. (2009). Mortality of women from intimate partner violence in South Africa: A national epidemiological study. *Violence and Victims, 24*(4), 546–556.
- Ahmed, S., Ackerman, V., Faught, P., & Langston, C. (2008). Profound hypoxemia and pulmonary hypertension in a 7-month-old infant: Late presentation of alveolar capillary dysplasia. *Pediatric Critical Care Medicine: A Journal of the Society of Critical Care Medicine and the World Federation of Pediatric Intensive and Critical Care Societies, 9*(6), e43–e46.
- Aihara, M. (2011). Continuous facial pain after hitting the face: Diagnostic pitfall. *The Journal of Trauma, 71*(4), E100.
- American Nurses Association (ANA). (2010). *Nursing's social policy statement* (3rd ed.). Silver Spring, MD: Nursesbooks.org.
- Andrew, T. A., & Fallon, K. K. (2007). Asphyxial games in children and adolescents. *The American Journal of Forensic Medicine and Pathology, 28*(4), 303–307.
- Anscombe, A., & Knight, B. (1996). Case report. Delayed death after pressure on the neck: Possible causal mechanisms and implications for mode of death in manual strangulation discussed. *Forensic Science International, 78*(3), 193–197.
- Asamura, H., Ito, M., & Fukushima, H. (2009). An unusual suicide case of the combination of asphyxia. *The American Journal of Forensic Medicine and Pathology, 30*(2), 215–216.
- Asamura, H., Oki, T., Masao, O., & Fukushima, H. (2010). Unusual body posture after death leading to signs of strangulation. *The American Journal of Forensic Medicine and Pathology, 31*(2), 195–197.
- Atilgan, M. (2010). A case of suicidal ligature strangulation by using a tourniquet method. *The American Journal of Forensic Medicine and Pathology, 31*(1), 85–86.
- Atkins, B. Z., Abbate, S., Fisher, S. R., & Vaslef, S. N. (2004). Current management of laryngotracheal trauma: Case report and literature review. *Journal of Trauma and Acute Care Surgery, 56*(1), 185–190.
- Azmak, D. (2006). Asphyxial deaths: A retrospective study and review of the literature. *The American Journal of Forensic Medicine and Pathology, 27*(2), 134–144.
- Behrendt, N., & Modvig, J. (1995). The lethal paraphiliac syndrome: Accidental autoerotic deaths in Denmark 1933–1990. *The American Journal of Forensic Medicine and Pathology, 16*(3), 232–237.
- Bergin, A., & Berkowitz, R. (2012). Domestic violence in military families: Non-fatal strangulation. *Maryland Medicine: MM: A Publication of MEDCHI, the Maryland State Medical Society, 13*(3), 19, 29.
- Berrios, D. C., & Grady, D. (1991). Domestic violence. Risk factors and outcomes. *The Western Journal of Medicine, 155*(2), 133–135.
- Berzlanovich, A. M., Schopfer, J., & Keil, W. (2012). Deaths due to physical restraint. *Deutsches Arzteblatt International, 109*(3), 27–32.
- Betz, P., Hausmann, R., & Eisenmenger, W. (1998). A contribution to a possible differentiation between SIDS

and asphyxiation. *Forensic Science International*, 91(2), 147–152.

- Blanco Pampin, J., Morte Tamayo, N., Hinojal Fonseca, R., Payne-James, J. J., & Jerreat, P. (2002). Delayed presentation of carotid dissection, cerebral ischemia, and infarction following blunt trauma: Two cases. *Journal of Clinical Forensic Medicine*, 9(3), 136–140.
- Block, C. R., Devitt, C., Fonda, D., Engel, B., Fugate, M., & Martin, C. (2000). The Chicago women's health risk study: Risk of serious injury or death in intimate violence, a collaborative research project. *Illinois Criminal Justice Information Authority*,
- Bockholdt, B., Maxeiner, H., & Hegenbarth, W. (2005). Factors and circumstances influencing the development of hemorrhages in livor mortis. *Forensic Science International*, 149(2), 133–137.
- Bockholdt, B., Hempelmann, M., & Maxeiner, H. (2003). Experimental investigations of fractures of the upper thyroid horns. *Legal Medicine (Tokyo, Japan)*, 5, S252–S255.
- Bockholdt, B., & Maxeiner, H. (2002). Hemorrhages of the tongue in the postmortem diagnostics of strangulation. *Forensic Science International*, 126(3), 214–220.
- Bohnert, M., Faller-Marquardt, M., Lutz, S., Amberg, R., Weisser, H., & Pollak, S. (2001). Transfer of biological traces in cases of hanging and ligature strangulation. *Forensic Science International*, 116(2), 107–115.
- Bouwer, C., & Stein, D. (1999). Panic disorder following torture by suffocation is associated with predominantly respiratory symptoms. *Psychological Medicine*, 29(1), 233–236.
- Breitmeier, D., Mansouri, F., Albrecht, K., Böhm, U., Tröger, H., & Kleemann, W. (2003). Accidental autoerotic deaths between 1978 and 1997: Institute of legal medicine, medical school Hannover. *Forensic Science International*, 137(1), 41–44.
- Brenner, D. J. (2002). Estimating cancer risks from pediatric CT: Going from the qualitative to the quantitative. *Pediatric Radiology*, 32(4), 228–231.
- Bridgell, J., Mallon, A., & DeFatta, R. A., Chowdhury, F., & Nagorsky, M. (2012). Dysphagia after strangulation. *Ear, Nose & Throat Journal*, 91(9), E30–E31.
- Brodsky, J. B., & Lemmens, H. J. (2003). Left double-lumen tubes: Clinical experience with 1,170 patients. *Journal of Cardiothoracic and Vascular Anesthesia*, 17(3), 289–298.
- Browning, S., & Whittet, H. (2000). A new and clinically symptomatic variant of thyroid cartilage anatomy. *Clinical Anatomy*, 13(4), 294–297.
- Busse, W. W., Wanner, A., Adams, K., Reynolds, H. Y., Castro, M., Chowdhury, B., & Sullivan, E. J. (2005). Investigative bronchoprovocation and bronchoscopy in airway diseases. *American Journal of Respiratory and Critical Care Medicine*, 172(7), 807–816.
- Butz, R. O. (1968). Length and cross-section growth patterns in the human trachea. *Pediatrics*, 42(2), 336–341.
- Byard, R. W., Hucker, S. J., & Hazelwood, R. R. (1993). Fatal and near-fatal autoerotic asphyxia episodes in women: Characteristic features based on a review of nine cases. *The American Journal of Forensic Medicine and Pathology*, 14(1), 70.

- Byard, R. W., & Winskog, C. (2012). Autoerotic death: Incidence and age of victims—A population-based study. *Journal of Forensic Sciences*, *57*(1), 129–131.
- Campbell, J. C. (2002). Health consequences of intimate partner violence. *The Lancet*, *359*(9314), 1331–1336.
- Campbell, J. C., Glass, N., Sharps, P. W., Laughon, K., & Bloom, T. (2007). Intimate partner homicide: Review and implications of research and policy. *Trauma, Violence & Abuse*, *8*(3), 246–269.
- Campbell, J. C., Webster, D. W., & Glass N. (2009). The danger assessment: Validation of a lethality risk assessment instrument for intimate partner femicide. *Journal of Interpersonal Violence*, *24*(4), 653–674.
- Campobasso, C. P., Colonna, M. F., Carabellese, F., Grattagliano, I., Candelli, C., Morton, R. J., & Catanesi, R. (2009). A serial killer of elderly women: Analysis of a multi-victim homicide investigation. *Forensic Science International*, *185*(1), e7–e11.
- Car, M. (2000). Increasing awareness about possible neurological alterations in brain status secondary to intimate violence. *Brain Injury Source*, *4*(2), 30–37. Retrieved May 5, 2016, from [http://www.doj.state.or.us/victims/pdf/increasing\\_awareness\\_about\\_possible\\_neurological\\_alterations.pdf](http://www.doj.state.or.us/victims/pdf/increasing_awareness_about_possible_neurological_alterations.pdf)
- Carson, D., & Pounder, D. (1996). Transport strangulation. *Forensic Science International*, *82*(2), 191–192.
- Cartwright, N. E. K., Hussin, H. M., Biswas, S., Majid, M. A., Potts, M. J., Kabala, J., & Mayer, E. J. (2007). Subperiosteal orbital hemorrhage following self-strangulation. *Annals of Ophthalmology*, *39*(4), 345–347.
- Chan, T. C., Vilke, G. M., & Neuman, T. (1998). Re-examination of custody restraint position and positional asphyxia. *The American Journal of Forensic Medicine and Pathology*, *19*(3), 201–205.
- Chang, A. B., Moloney, G. E., Harms, P. J., & Masters, I. B. (2004). Endoscopic intratracheal carbon dioxide measurements during pediatric flexible bronchoscopy. *Paediatric Anaesthesia*, *14*(8), 650–655.
- Cheddie, S., Pillay, B., & Goga, R. (2013). Bilateral blunt carotid artery injury: A case report and review of the literature. *South African Journal of Surgery*, *51*(2), 77–83.
- Chou, F., & Conway, M. D. (1998). History of ocular anesthesia. *Ophthalmology Clinics*, *11*(1), 1–9.
- Christe, A., Oesterhelweg, L., Ross, S., Spendlove, D., Bolliger, S., Vock, P., & Thali, M. J. (2010). Can MRI of the neck compete with clinical findings in assessing danger to life for survivors of manual strangulation? A statistical analysis. *Legal Medicine (Tokyo, Japan)*, *12*(5), 228–232.
- Christe, A., Thoeny, H., Ross, S., Spendlove, D., Tshering, D., Bolliger, S., & Oesterhelweg, L. (2009). Life-threatening versus non-life-threatening manual strangulation: Are there appropriate criteria for MR imaging of the neck? *European Radiology*, *19*(8), 1882–1889.
- Clarot, F., Vaz, E., Papin, F., & Proust, B. (2005). Fatal and non-fatal bilateral delayed carotid artery dissection after manual strangulation. *Forensic Science International*, *149*(2), 143–150.
- Cole, F. (1957). Pediatric formulas for the anesthesiologist. *AMA Journal of Diseases of Children*, *94*(6), 672–673.

- Collins, K. A., & Presnell, S. E. (2006). Elder homicide: A 20-year study. *The American Journal of Forensic Medicine and Pathology*, 27(2), 183–187.
- Comer, B. T., & Gal, T. J. (2012). Recognition and management of the spectrum of acute laryngeal trauma. *The Journal of Emergency Medicine*, 43(5), e289–e293.
- Cotton, R. T. (1984). Pediatric laryngotracheal stenosis. *Journal of Pediatric Surgery*, 19(6), 699–704.
- Crosby, S. S., Mohan, S., Di Loreto, C., & Spiegel, J. H. (2010). Head and neck sequelae of torture. *The Laryngoscope*, 120(2), 414–419.
- Davies, S. J. (2010). "C3, 4, 5 keeps the diaphragm alive." Is phrenic nerve palsy part of the pathophysiological mechanism in strangulation and hanging? Should diaphragm paralysis be excluded in survived cases? A review of the literature. *The American Journal of Forensic Medicine and Pathology*, 31(1), 100–102.
- Davison, A. M., & Williams, E. J. (2012). Microscopic evidence of previous trauma to the hyoid bone in a homicide involving pressure to the neck. *Forensic Science, Medicine, and Pathology*, 8(3), 307–311.
- Dayapala, A., Samarasekera, A., & Jayasena, A. (2012). An uncommon delayed sequela after pressure on the neck: An autopsy case report. *The American Journal of Forensic Medicine and Pathology*, 33(1), 80–82.
- Dean, R., & Mulligan, J. (2009). Providing first aid and assisting forensic investigations. *Nursing Standard*, 24(8), 35.
- Delmonte, C., & Capelozzi, V. L. (2001). Morphologic determinants of asphyxia in lungs: A semi-quantitative study in forensic autopsies. *The American Journal of Forensic Medicine and Pathology*, 22(2), 139–149.
- Demierre, N., Wyler, D., Zollinger, U., Bolliger, S., & Plattner, T. (2009). Elevated body core temperature in medico-legal investigation of violent death. *The American Journal of Forensic Medicine and Pathology*, 30(2), 155–158.
- Demirci, S., Dogan, K. H., Erkol, Z., & Deniz, I. (2009). A series of complex suicide. *The American Journal of Forensic Medicine and Pathology*, 30(2), 152–154.
- Demirci, S., Dogan, K. H., Erkol, Z., & Gunaydin, G. (2009). Suicide by ligature strangulation: Three case reports. *The American Journal of Forensic Medicine and Pathology*, 30(4), 369–372.
- Di Nunno, N., Costantinides, F., Conticchio, G., Mangiatordi, S., Vimercati, L., & Di Nunno, C. (2002). Self-strangulation: An uncommon but not unprecedented suicide method. *The American Journal of Forensic Medicine and Pathology*, 23(3), 260–263.
- DiMaio, V. J. (2000). Homicidal asphyxia. *The American Journal of Forensic Medicine and Pathology*, 21(1), 1–4.
- Di Paolo, M., Guidi, B., Bruschini, L., Vessio, G., Domenici, R., & Ambrosino, N. (2009). Unexpected delayed death after manual strangulation: Need for care examination in the emergency room. *Monaldi Archives for Chest Disease*, 71(3), 132–134.
- Douglas, H., & Fitzgerald, R. B. (2014). Strangulation, domestic violence and the legal response. *Sydney Law Review*, 36(2), 231–254.
- Downing, R. (2006). Manual and ligature strangulation. *On the Edge*, 12(2), 1.

- Duband, S., Timoshenko, A. P., Morrison, A. L., Prades, J. M., Debout, M., & Peoc'h, M. (2009). Ear bleeding: A sign not to be underestimated in cases of strangulation. *The American Journal of Forensic Medicine and Pathology*, *30*(2), 175–176.
- Dutton, D. G. (2002). Personality dynamics of intimate abusiveness. *Journal of Psychiatric Practice*, *8*(4), 216–228.
- Eckel, H. E., Sprinzl, G. M., Koebke, J., Pototschnig, C., Sittel, C., & Stennert, E. (1999). Morphology of the human larynx during the first five years of life studied on whole organ serial sections. *Annals of Otolaryngology, Rhinology & Laryngology*, *108*(3), 232–238.
- Egge, M. K., Berkowitz, C. D., Toms, C., & Sathyavagiswaran, L. (2010). The choking game: A cause of unintentional strangulation. *Pediatric Emergency Care*, *26*(3), 206–208.
- Eldredge, K., Huggins, E., & Pugh, L. C. (2012). Alternate light sources in sexual assault examinations: An evidence-based practice project. *Journal of Forensic Nursing*, *8*(1), 39–44.
- Ely, S. F., & Hirsch, C. S. (2000). Asphyxial deaths and petechiae: A review. *Journal of Forensic Sciences*, *45*(6), 1274–1277.
- Ernoehazy, W., Jr. (2016, January 19). Hanging injuries and strangulation. *Medscape*. Retrieved May 5, 2016, from <http://www.Emedicine.com/emerg/topic227>
- Fais, P., Giraudo, C., Viero, A., Miotto, D., Bortolotti, F., Tagliaro, F., Montisci, M., & Cecchetto, G. (2016). Micro computed tomography features of laryngeal fractures in a case of fatal manual strangulation. *Legal Medicine (Tokyo, Japan)*, *18*, 85–89. doi: 10.1016/j.legalmed.2016.01.001.
- Faugno, D., Waszak, D., Strack, G. B., Brooks, M. A., & Gwinn, C. G. (2013). Strangulation forensic examination: Best practice for health care providers. *Advanced Emergency Nursing Journal*, *35*(4), 314–327.
- Fernando, T., & Byard, R. W. (2013). Positional asphyxia without active restraint following an assault. *Journal of Forensic Sciences*, *58*(6), 1633–1635.
- Fieguth, A., Albrecht, U., Bertolini, J., & Kleemann, W. (2003). Intracartilaginous haemorrhagic lesions in strangulation? *International Journal of Legal Medicine*, *117*(1), 10–13.
- Fieguth, A., Franz, D., Lessig, R., & Kleemann, W. J. (2003). Fatal trauma to the neck: Immuno-histo-chemical study of local injuries. *Forensic Science International*, *135*(3), 218–225.
- Fineron, P. W., Turnbull, J. A., & Busuttill, A. (1995). Fracture of the hyoid bone in survivors of attempted manual strangulation. *Journal of Clinical Forensic Medicine*, *2*(4), 195–197.
- Firdose, R., & Elamin, E. M. (2004). Pulmonary edema secondary to dynamic tracheal collapse. *Journal of Bronchology & Interventional Pulmonology*, *11*(2), 118–121.
- Fisher, J. W., & Shelton, A. J. (2006). Survivors of domestic violence: Demographics and disparities in visitors to an interdisciplinary specialty clinic. *Family & Community Health*, *29*(2), 118–130.
- Fitzsimons, M. G., Peralta, R., & Hurford, W. (2005). Cricoid fracture after physical assault. *Journal of Trauma and Acute Care Surgery*, *59*(5), 1237–1238.
- Fortune, S. A., & Hawton, K. (2005). Deliberate self-harm in children and adolescents: A research update. *Current Opinion in Psychiatry*, *18*(4), 401–406.



- Fracasso, T., & Pfeiffer, H. (2008). Simon's bleedings in case of incomplete hanging: A case report. *The American Journal of Forensic Medicine and Pathology*, 29(4), 352–353.
- Funk, M., & Schuppel, J. (2003). Strangulation injuries. *WMJ: Official Publication of the State Medical Society of Wisconsin*, 102(3), 41–45.
- Geddes, J., & Whitwell, H. (2004). Inflicted head injury in infants. *Forensic Science International*, 146(2), 83–88.
- Geevasinga, N., Archer, J. S., & Ng, K. (2014). Choking, asphyxiation and the insular seizure. *Journal of Clinical Neuroscience: Official Journal of the Neurosurgical Society of Australasia*, 21(4), 688–689.
- Giger, R., Friedrich, J. P., Dulguerov, P., & Landis, B. N. (2004). Pneumo-pericardium after manual strangulation. *The American Journal of Medicine*, 116(11), 788–790.
- Gill, J. R., Cavalli, D. P., Ely, S. F., & Stahl-Herz, J. (2013). Homicidal neck compression of females: Autopsy and sexual assault findings. *Academic Forensic Pathology*, 3(4), 454–457.
- Gilkeson, R., Ciancibello, L. M., Hejal, R. B., Montenegro, H. D., & Lange, P. (2001). Tracheobronchomalacia: Dynamic airway evaluation with multidetector CT. *American Journal of Roentgenology*, 176(1), 205–210.
- Glass, N., Laughon, K., Campbell, J., Block, C. R., Hanson, G., Sharps, P. W., & Taliaferro, E. (2008). Non-fatal strangulation is an important risk factor for homicide of women. *The Journal of Emergency Medicine*, 35(3), 329–335.
- Godin, A., Kremer, C., & Sauvageau, A. (2012). Fracture of the cricoid as a potential pointer to homicide: A 6-year retrospective study of neck structures fractures in hanging victims. *The American Journal of Forensic Medicine and Pathology*, 33(1), 4–7.
- Goodman, R. A., Mercy, J. A., & Rosenberg, M. L. (1986). Drug use and interpersonal violence. Barbiturates detected in homicide victims. *American Journal of Epidemiology*, 124(5), 851–855.
- Gosink, P. D., & Jumbelic, M. I. (2000). Autoerotic asphyxiation in a female. *The American Journal of Forensic Medicine and Pathology*, 21(2), 114–118.
- Goudy, S. L., Miller, F. B., & Bumpous, J. M. (2002). Neck crepitation: Evaluation and management of suspected upper aerodigestive tract injury. *The Laryngoscope*, 112(5), 791–795.
- Gowens, P. A., Davenport, R. J., Kerr, J., Sanderson, R. J., & Marsden, A. K. (2003). Survival from accidental strangulation from a scarf resulting in laryngeal rupture and carotid artery stenosis: The "Isadora Duncan syndrome." A case report and review of literature. *Emergency Medicine Journal: EMJ*, 20(4), 391–393.
- Graham, E. A. M., & Rutty, G. N. (2008). Investigation into “normal” background DNA on adult necks: Implications for DNA profiling of manual strangulation victims. *Journal of Forensic Sciences*, 53(5), 1074–1082.
- Grattagliano, I., Troccoli, G., Zelano, C., & Catanesi, R. (2013). Incaprettamento: An unusual homicide by ligature strangulation. *International Journal of Criminology and Sociology*, 2, 10–12.
- Gupta, B., Sinha, C., Kumar, A., Dey, C., Ramchandani, S., Kumar, S., & Misra, M. (2012). Perioperative

- management of laryngotracheobronchial injury: Our experience in a level 1 trauma centre. *European Journal of Trauma and Emergency Surgery*, 38(5), 553–561.
- Gwinn, C., & Strack, G. B. (2012). *Welcome to train the trainer: Part 1 of training*. San Diego, CA: Training Institute on Strangulation Prevention.
- Hackett, A. M., & Kitsko, D. J. (2013). Evaluation and management of pediatric near-hanging injury. *International Journal of Pediatric Otorhinolaryngology*, 77(11), 1899–1901.
- Häkkänen, H. (2005). Homicide by ligature strangulation in Finland: Offence and offender characteristics. *Forensic Science International*, 152(1), 61–64.
- Hanna, S. (2004). A study of 13 cases of near-hanging presenting to an accident and emergency department. *Injury*, 35(3), 253–256.
- Hansen, S. H. (2001). Laryngeal crepitus: An aid to diagnosis in non-fatal strangulation. *Medicine, Science, and the Law*, 41(4), 284–286.
- Härm, T., & Rajs, J. (1981). Types of injuries and interrelated conditions of victims and assailants in attempted and homicidal strangulation. *Forensic Science International*, 18(2), 101–123.
- Hawley, D. A. (2002, June). *Death by strangulation*. Paper presented at the conference: How to Improve Your Investigation and Prosecution of Domestic Violence and Strangulation Cases. Delaware, OH.
- Hawley, D. A. (n.d.). *Forensic medical findings in fatal and non-fatal intimate partner strangulation assaults*. Retrieved on May 6, 2016, from <http://dhss.alaska.gov/ocs/Documents/childrensjustice/strangulation/16.%20Forensic%20Medical%20Findings%20in%20Fatal%20and%20Non-Fatal%20Intimate%20Partner%20Strangulation%20Assaults%20-%20Hawley%20-%202012.pdf>
- Hawley, D. A., McClane, G. E., & Strack, G. B. (2001). A review of 300 attempted strangulation cases. Part III: Injuries in fatal cases. *The Journal of Emergency Medicine*, 21(3), 317–322.
- Hibbert, M., Lannigan, A., Raven, J., Landau, L., & Phelan, P. (1995). Gender differences in lung growth. *Pediatric Pulmonology*, 19(2), 129–134.
- Hinderliter, D., Doughty, A. S., Delaney, K., Pitula, C. R., & Campbell, J. (2003). The effect of intimate partner violence education on nurse practitioners' feelings of competence and ability to screen patients. *Journal of Nursing Education*, 42(10), 449–454.
- Ho, L. Y., & Abdelghani, W. M. (2007). Valsalva retinopathy associated with the choking game. *Seminars in Ophthalmology*, 22(2), 63–65.
- Holbrook, D. S., & Jackson, M. C. (2013). Use of an alternative light source to assess strangulation victims. *Journal of Forensic Nursing*, 9(3), 140–145.
- Hoo, A., Dezateux, C., Hanrahan, J. P., Cole, T. J., Tepper, R. S., & Stocks, J. (2002). Sex-specific prediction equations for V maxFRC in infancy: A multicenter collaborative study. *American Journal of Respiratory and Critical Care Medicine*, 165(8), 1084–1092.
- Hori, A., Hirose, G., Kataoka, S., Tsukada, K., Furui, K., & Tonami, H. (1991). Delayed post anoxic encephalopathy after strangulation serial neuroradiological and neurochemical studies. *Archives of Neurology*, 48(8), 871–874.

- Horn, B. K., & Schunck, B. G. (1981). Determining optical flow. In *1981 Technical Symposium East* (pp. 319–331). Bellingham, WA: International Society for Optics and Photonics.
- Hoyt, C. A. (2006). Integrating forensic science into nursing processes in the ICU. *Critical Care Nursing Quarterly*, *29*(3), 259–270.
- Huxley, A. K., Froede, R. C., & Birkby, W. H. (2001). Strangulation of pregnant woman leads to one first-degree murder indictment for the death of the mother: A medicolegal reconsideration of maternal/fetal homicide. *The American Journal of Forensic Medicine and Pathology*, *22*(1), 51–54.
- Iacovou, E., Nayar, M., Fleming, J., & Lew-Gor, S. (2011). A pain in the neck: A rare case of isolated hyoid bone trauma. *Journal of Surgical Case Reports*, *7*, 3.
- Ibsen, L. M., & Koch, T. (2002). Submersion and asphyxial injury. *Critical Care Medicine*, *30*(11), S402–S408.
- Iserson, K. V. (1984). Strangulation: A review of ligature, manual, and postural neck compression injuries. *Annals of Emergency Medicine*, *13*(3), 179–185.
- Ishida, K., Zhu, B., Quan, L., Fujita, M., & Maeda, H. (2000). Pulmonary surfactant-associated protein A levels in cadaveric sera with reference to the cause of death. *Forensic Science International*, *109*(2), 125–133.
- Janssen, W., Koops, E., Anders, S., Kuhn, S., & Püschel, K. (2005). Forensic aspects of 40 accidental autoerotic deaths in northern Germany. *Forensic Science International*, *147*, S61–S64.
- Jesseph, J. E., & Merendino, K. A. (1957). The dimensional interrelationships of the major components of the human tracheobronchial tree. *Surgery, Gynecology & Obstetrics*, *105*(2), 210–214.
- Joshi, M., Thomas, K. A., & Sorenson, S. B. (2012). "I didn't know I could turn colors": Health problems and health care experiences of women strangled by an intimate partner. *Social Work in Health Care*, *51*(9), 798–814.
- Kanchan, T., Raghavendra Babu, Y. P., Atreya, A., & Acharya, J. (2016). Ligature mark on the face – Forensic implications. *The Medico Legal Journal*, *84*(3), 138–141. doi: 10.1177/0025817216630658.
- Karch, D. L., Logan, J. E., McDaniel, D., Parks, S., Patel, N., & Centers for Disease Control and Prevention (CDC). (2012). Surveillance for violent deaths—National Violent Death Reporting System, 16 states, 2009. *Morbidity and Mortality Weekly Report. Surveillance Summaries*, *61*(6), 1–43.
- Kaufman, H. J., Ciraulo, D. L., & Burns, R. P. (1999). Traumatic fracture of the hyoid bone: Three case presentations of cardiorespiratory compromise secondary to missed diagnosis. *The American Surgeon*, *65*(9), 877–880.
- Kempton, M., Ross, S., Spendlove, D., Flach, P., Preiss, U., Thali, M., & Bolliger, S. (2009). Post-mortem imaging of laryngo-hyoid fractures in strangulation incidents: First results. *Legal Medicine (Tokyo, Japan)*, *11*(6), 267–271.
- Kerby, J. D., May, A. K., Gomez, C. R., & Rue, L. W., III. (2000). Treatment of bilateral blunt carotid injury using percutaneous angioplasty and stenting: Case report and review of the literature. *Journal of Trauma and Acute Care Surgery*, *49*(4), 784–787.
- Khimenko, L. P., Esham, H. R., & Ahmed, W. (2000). Spontaneous internal carotid artery dissection. *Southern Medical Journal*, *93*(10), 1011–1016.

- Khokhlov, V. D. (2001). Calculation of tension exerted on a ligature in incomplete hanging. *Forensic Science International*, 123(2), 172–177.
- Khokhlov, V. D. (1996). The mechanisms of the formation of injuries to the hyoid bone and laryngeal and tracheal cartilages in compression of the neck. [Mekhanizmy obrazovaniia povrezhdenii pod"iazychnoi kosti, khriashchei gortani i trakhei pri sdavlenii shei] *Sudebno-Meditsinskaia Ekspertiza*, 39(3), 13–16.
- Kiani, S. H., & Simes, D. C. (2000). Delayed bilateral internal carotid artery thrombosis following accidental strangulation. *British Journal of Anaesthesia*, 84(4), 521–524.
- King, G. G., Brown, N. J., Diba, C., Thorpe, C. W., Munoz, P., Marks, G. B., & Salome, C. M. (2005). The effects of body weight on airway calibre. *The European Respiratory Journal*, 25(5), 896–901.
- Kleemann, W.J., Wiechern, V., Schuck, M., & Tröger, H. (1995). Intrathoracic and subconjunctival petechiae in sudden infant death syndrome (SIDS). *Forensic Science International*, 72(1), 49–54.
- Kleinsasser, N. H., Priemer, F. G., Schulze, W., & Kleinsasser, O. F. (2000). External trauma to the larynx: Classification, diagnosis, therapy. *European Archives of Oto-Rhino-Laryngology*, 257(8), 439–444.
- Klopfstein, U., Kamber, J., & Zimmermann, H. (2010). "On the way to light the dark": A retrospective inquiry into the registered cases of domestic violence towards women over a six year period with a semi-quantitative analysis of the corresponding forensic documentation. *Swiss Medical Weekly*, 140, w13047.
- Knight, J. A., & Taft, C. T. (2004). Assessing neuropsychological concomitants of trauma and PTSD. In J. P. Wilson & T. M. Keane (Eds.), *Assessing psychological trauma and PTSD* (2nd ed.) (pp. 344–388). New York, NY: Guilford Press.
- Knox Cartwright, N. E., Hussin, H. M., Biswas, S., Majid, M. A., Potts, M. J., Kabala, J., & Mayer, E. J. (2007). Subperiosteal orbital hemorrhage following self-strangulation. *Annals of Ophthalmology (Skokie, Illinois)*, 39(4), 345–347.
- Koh, M. S., Hsu, A. A. L., & Eng, P. (2003). Negative pressure pulmonary edema in the medical intensive care unit. *Intensive Care Medicine*, 29(9), 1601–1604.
- Kohli, A., Verma, S., & Agarwal, B. (1996). Accidental strangulation in a rickshaw. *Forensic Science International*, 78(1), 7–11.
- Kristensen, M. E., Lynnerup, N., & Sejrsen, B. (2006). Comparison of hand marks in manual strangulation: An experimental study. *Journal of Forensic Sciences*, 51(2), 381–385.
- Kwako, L. E., Glass, N., Campbell, J., Melvin, K. C., Barr, T., & Gill, J. M. (2011). Traumatic brain injury in intimate partner violence: A critical review of outcomes and mechanisms. *Trauma, Violence & Abuse*, 12(3), 115–126.
- Lambe, A., Püschel, K., & Anders, S. (2009). Extensive petechiae in attempted self-strangulation. *Journal of Forensic Sciences*, 54(1), 212–215.
- Langevin, R., Ben-Aron, M., Wright, P., Marchese, V., & Handy, L. (1988). The sex killer. *Annals of Sex Research*, 1(2), 263–301.

- Laughon, K., Glass, N., & Worrell, C. (2009). Review and analysis of laws related to strangulation in 50 states. *Evaluation Review*, 33(4), 358–369.
- Laughon, K., Renker, P., Glass, N., & Parker, B. (2008). Revision of the abuse assessment screen to address nonlethal strangulation. *Journal of Obstetric, Gynecologic, and Neonatal Nursing*, 37(4), 502–507.
- Le Blanc-Louvry, I., Papin, F., Vaz, E., & Proust, B. (2013). Cervical arterial injury after strangulation—Different types of arterial lesions. *Journal of Forensic Sciences*, 58(6), 1640–1643.
- Lees, S., Phimister, D., Broughan, C., Dignon, A., & Brown, M. (2013). Domestic violence: The base of the iceberg. *British Journal of Midwifery*, 21(7), 493–498.
- Li, D., Ishikawa, T., Quan, L., Zhao, D., Michiue, T., Zhu, B., & Maeda, H. (2010). Morphological analysis of astrocytes in the hippocampus in mechanical asphyxiation. *Legal Medicine (Tokyo, Japan)*, 12(2), 63–67.
- Li, D., Zhu, B., Ishikawa, T., Zhao, D., Michiue, T., & Maeda, H. (2006). Immunohistochemical distribution of S-100 protein in the cerebral cortex with regard to the cause of death in forensic autopsy. *Legal Medicine (Tokyo, Japan)*, 8(2), 78–85.
- Li, W., Liu, D., Gallina, K., & Zhou, Y. (2016, February 24). Delayed death caused by haematoma after manual strangulation: A rare case. *The British Journal of Oral and Maxillofacial Surgery*. doi:10.1016/j.bjoms.2016.02.004.
- Lin, P., & Gill, J. R. (2011). Homicides of pregnant women. *The American Journal of Forensic Medicine and Pathology*, 32(2), 161–163.
- Linden, J. A., Lewis-O'Connor, A., & Jackson, M. C. (2007). Forensic examination of adult victims and perpetrators of sexual assault. (2008). In J. S. Olshaker, M. C. Jackson & W. S. Smock (Eds.), *Forensic emergency medicine* (2nd ed.) (pp. 85–125). Philadelphia, PA: Lippincott, Wilkins & Williams.
- Line, W. S., Jr., Stanley, R. B., Jr., & Choi, J. H. (1985). Strangulation: A full spectrum of blunt neck trauma. *The Annals of Otolaryngology, Rhinology, and Laryngology*, 94(6), 542–546.
- Linkletter, M., Gordon, K., & Dooley, J. (2010). The choking game and YouTube: A dangerous combination. *Clinical Pediatrics*, 49(3), 274–279.
- Lombardi, M., Canter, J., Patrick, P. A., & Altman, R. (2015). Is fluorescence under an alternate light source sufficient to accurately diagnose subclinical bruising? *Journal of Forensic Sciences*, 60(2), 444–449.
- Losek, J. D., Tecklenburg, F. W., & White, D. R. (2008). Blunt laryngeal trauma in children: Case report and review of initial airway management. *Pediatric Emergency Care*, 24(6), 370–373.
- Lupascu, C., Lupascu, C., & Beldiman, D. (2003). Mechanical asphyxia by three different mechanisms. *Legal Medicine (Tokyo, Japan)*, 5(2), 110–111.
- Madea, B., Schmidt, P., Kernbach-Wighton, G., & Doberentz, E. (2015). Strangulation--Suicide at the wheel. *Legal Medicine (Tokyo, Japan)*, 17(6), 512–516. doi: 10.1016/j.legalmed.2015.11.001.
- Maguire, S. A., Watts, P. O., Shaw, A. D., Holden, S., Taylor, R. H., Watkins, W. J., & Kemp, A. M. (2013). Retinal haemorrhages and related findings in abusive and non-abusive head trauma: A systematic review. *Eye (London, England)*, 27(1), 28–36.

- Maher, J. L., Mahabir, R. C., & Read, L. A. (2011). Acute macroglossia in the pediatric patient: Worth a look. *Pediatric Emergency Care*, 27(10), 948–949.
- Makwana, N., Evans, H. M., Moore, D., & Berry, K. (2001). Two cases of near asphyxiation in children, using non-releasing plastic garden ties. *Emergency Medicine Journal: EMJ*, 18(3), 229–230.
- Malek, A. M., Higashida, R. T., Halbach, V. V., Dowd, C. F., Phatouros, C. C., Lempert, T. E., & Stoney, R. (2000). Patient presentation, angiographic features, and treatment of strangulation-induced dissection of the internal carotid artery: Report of three cases. *Journal of Neurosurgery*, 92(3), 481–487.
- Malek, A. M., Higashida, R. T., Phatouros, C. C., & Halbach, V. V. (1999). A strangled wife. *The Lancet*, 353(9161), 1324.
- Mansell, A. L., Bryan, A. C., & Levison, H. (1977). Relationship of lung recoil to lung volume and maximum expiratory flow in normal children. *Journal of Applied Physiology: Respiratory, Environmental and Exercise Physiology*, 42(6), 817–823.
- Mansfield, M., & McGinty, J. S. (2008). Responding to hanging injuries. *Nursing2008*, 38(5), 56cc1, 56cc3.
- Martz, D. (2003). Behavioral treatment for a female engaging in autoerotic asphyxiation. *Clinical Case Studies*, 2(3), 236–242.
- Marx, J., Walls, R., & Hockberger, R. (2014). *Rosen's emergency medicine—Concepts and clinical practice*. Philadelphia, PA: Elsevier.
- Masters, I., Chang, A., Patterson, L., Wainwright, C., Buntain, H., Dean, B., & Francis, P. (2002). Series of laryngomalacia, tracheomalacia, and bronchomalacia disorders and their associations with other conditions in children. *Pediatric Pulmonology*, 34(3), 189–195.
- Masters, I. B., & Cooper, P. (2002). Paediatric flexible bronchoscopy. *Journal of Paediatrics and Child Health*, 38(6), 555–559.
- Masters, I. B., Eastburn, M. M., Francis, P. W., Wootton, R., Zimmerman, P. V., Ware, R. S., & Chang, A. B. (2005). Quantification of the magnification and distortion effects of a pediatric flexible video-bronchoscope. *Respiratory Research*, 6, 16.
- Masters, I. B., Eastburn, M. M., Wootton, R., Ware, R. S., Francis, P. W., Zimmerman, P. V., & Chang, A. B. (2005). A new method for objective identification and measurement of airway lumen in paediatric flexible videobronchoscopy. *Thorax*, 60(8), 652–658.
- Maxeiner, H. (1998). “Hidden” laryngeal injuries in homicidal strangulation: How to detect and interpret these findings. *Journal of Forensic Sciences*, 43(4), 784–791.
- Maxeiner, H., & Bockholdt, B. (2003). Homicidal and suicidal ligature strangulation—A comparison of the post-mortem findings. *Forensic Science International*, 137(1), 60–66.
- Maxeiner, H., & Jekat, R. (2010). Resuscitation and conjunctival petechial hemorrhages. *Journal of Forensic and Legal Medicine*, 17(2), 87–91.
- McClane, G. E., Strack, G. B., & Hawley, D. (2001). A review of 300 attempted strangulation cases. Part II: Clinical evaluation of the surviving victim. *The Journal of Emergency Medicine*, 21(3), 311–315.

- McClave, J. L., Russell, P. J., Lyren, A., O'Riordan, M. A., & Bass, N. E. (2010). The choking game: Physician perspectives. *Pediatrics*, *125*(1), 82–87.
- McLean, M. (2012). Have you missed signs in a victim of strangulation? *Alberta RN/Alberta Association of Registered Nurses*, *68*(3), 18–19.
- McNeil, M. L., Amodi, H., & Brown, T. F. (2010). 30-year delayed presentation of hyoid strangulation fracture. *Journal of Otolaryngology - Head & Neck Surgery = Le Journal d'Oto-Rhino-Laryngologie et de Chirurgie Cervico-Faciale*, *39*(5), E26–E27.
- Mcquown, C., Frey, J., Steer, S., Fletcher, G. E., Kinkopf, B., Fakler, M., & Prulhiere, V. (2016). Prevalence of strangulation in survivors of sexual assault and domestic violence. *The American Journal of Emergency Medicine*, *34*(7), 1281–1285. doi: 10.1016/j.ajem.2016.04.029.
- Melkane, A. E., Matar, N. E., Haddad, A. C., & Zoghbi, A. C. (2010). Suicidal hanging attempt: Poor symptoms for a potentially lethal injury. *The Journal of Trauma*, *69*(4), E36.
- Miao, J., Su, C., Wang, W., Lin, H., Li, H., Lei, G., Li, Z. (2009). Delayed parkinsonism with a selective symmetric basal ganglia lesion after manual strangulation. *Journal of Clinical Neuroscience*, *16*(4), 573–575.
- Milligan, N., & Anderson, M. (1980). Conjugal disharmony: A hitherto unrecognised cause of strokes. *British Medical Journal*, *281*(6237), 421–422.
- Miziara, I. D., & Bertaccini, F. (2011). Three different mechanisms of death: An unusual form of a child murder by asphyxia. *The American Journal of Forensic Medicine and Pathology*, *32*(2), 164–165.
- Molacek, J., Baxa, J., Houdek, K., Ferda, J., & Treska, V. (2010). Bilateral post-traumatic carotid dissection as a result of a strangulation injury. *Annals of Vascular Surgery*, *24*(8), 1133. e9–e11.
- Mortelmans, L. J., Jutten, G. C., & Coene, L. (2003). Acute post-traumatic tension gastro thorax, a tension pneumothorax-like injury. *European Journal of Emergency Medicine*, *10*(4), 344–346.
- Moshirfar, M., Betts, B. S., Hsu, M., Holz, H. A., & McEntire, W. (2011). Bilateral total descemet's membrane detachments after strangulation. *Clinical Ophthalmology (Auckland, New Zealand)*, *5*, 1221–1222.
- Müller, E., Franke, W. G., & Koch, R. (1997). Thyreoglobulin and violent asphyxia. *Forensic Science International*, *90*(3), 165–170.
- Neto, H. S., Neville, I. S., Beer-Furlan, A., Tavares, W. M., Teixeira, M. J., & Paiva, W. S. (2014). Hemodynamic stroke caused by strangulation. *International Journal of Clinical and Experimental Medicine*, *7*(9), 2932.
- Nichols, S. D., McCarthy, M. C., Ekeh, A. P., Woods, R. J., Walusimbi, M. S., & Saxe, J. M. (2009). Outcome of cervical near-hanging injuries. *The Journal of Trauma*, *66*(1), 174–178.
- Nicoucar, K., Popova, N., Becker, M., & Dulguerov, P. (2008). Pseudo aneurysm of the external carotid artery after a blunt facial trauma. *The Journal of Trauma*, *65*(3), E24–E27. doi:10.1097/01.ta.0000209400.14212.a7
- Nikolic, S., Micic, J., Atanasijevic, T., Djokic, V., & Djonic, D. (2003). Analysis of neck injuries in hanging. *The American Journal of Forensic Medicine and Pathology*, *24*(2), 179–182.

- Niort, F., Godio-Raboutet, Y., Torrents, R., Adalian, P., Leonetti, G., Piercecchi-Marti, M. D., & Thollon, L. (2015). Transmission of force to the hyoid bone during manual strangulation: Simulation using finite element numerical models. *Forensic Science International*, *257*, 420–424. doi: 10.1016/j.forsciint.2015.10.013.
- O'Connor, P. J., Russell, J. D., & Moriarty, D. C. (1998). Anesthetic implications of laryngeal trauma. *Anesthesia & Analgesia*, *87*(6), 1283–1284.
- Oh, J. H., Min, H. S., Park, T. U., Sang, J. L., & Kim, S. E. (2007). Isolated cricoid fracture associated with blunt neck trauma. *Emergency Medicine Journal*, *24*(7), 505–506.
- Okazaki, J., Isono, S., Hasegawa, H., Sakai, M., Nagase, Y., & Nishino, T. (2004). Quantitative assessment of tracheal collapsibility in infants with tracheomalacia. *American Journal of Respiratory and Critical Care Medicine*, *170*(7), 780–785.
- Oxford, C. M., & Ludmir, J. (2009). Trauma in pregnancy. *Clinical Obstetrics and Gynecology*, *52*(4), 611–629.
- Paluch, M. (2013). Strangulation in domestic violence cases: Overcoming evidentiary challenges to reduce lethality. *Developments of New York State Family Law*.
- Pampin, J. B., Tamayo, N. M., Fonseca, R. H., Payne-James, J., & Jerreat, P. (2002). Delayed presentation of carotid dissection, cerebral ischemia, and infarction following blunt trauma: Two cases. *Journal of Clinical Forensic Medicine*, *9*(3), 136–140.
- Parks, S. E., Johnson, L. L., McDaniel, D. D., Gladden, M., & Centers for Disease Control and Prevention (CDC). (2014). Surveillance for violent deaths—National Violent Death Reporting System, 16 states, 2010. *Morbidity and Mortality Weekly Report. Surveillance Summaries*, *63*(1), 1–33.
- Patil, R. D., Bhambure, N. M., More, N., Athawale, A., & Shah, A. C. (1994). Survival after attempted strangulation. *The Journal of the Association of Physicians of India*, *42*(8), 644–645.
- Pego-Reigosa, R., Lopez-Lopez, S., Vazquez-Lopez, M. E., Armesto-Perez, V., Branäs-Fernández, F., Martínez-Vázquez, F., & Cortés-Laino, J. A. (2005). Sea wave-induced internal carotid artery dissection. *Neurology*, *64*(11), 1980.
- Pereira, F. L., Filho, L. I., Pavan, A. J., Farah, G. J., Gonçalves, E. A., Veltrini, V. C., & Camarini, E. T. (2007). Styloid-stylohyoid syndrome: Literature review and case report. *Journal of Oral and Maxillofacial Surgery: Official Journal of the American Association of Oral and Maxillofacial Surgeons*, *65*(7), 1346–1353.
- Plattner, T., Bolliger, S., & Zollinger, U. (2005). Forensic assessment of survived strangulation. *Forensic Science International*, *153*(2), 202–207.
- Pollanen, M. S., & McAuliffe, D. N. (1998). Intra-cartilaginous laryngeal haemorrhages and strangulation. *Forensic Science International*, *93*(1), 13–20.
- Pollanen, M. S. (2000). A triad of laryngeal hemorrhages in strangulation: A report of eight cases. *Journal of Forensic Sciences*, *45*(3), 614–618.
- Pollanen, M. S., Bulger, B., & Chiasson, D. A. (1995). The location of hyoid fractures in strangulation revealed by xeroradiography. *Journal of Forensic Sciences*, *40*(2), 303–305.
- Pollanen, M. S., & Chiasson, D. A. (1996). Fracture of the hyoid bone in strangulation: Comparison of fractured



- and un-fractured hyoids from victims of strangulation. *Journal of Forensic Sciences*, 41(1), 110–113.
- Pollanen, M. S., & Ubelaker, D. H. (1997). Forensic significance of the polymorphism of hyoid bone shape. *Journal of Forensic Sciences*, 42(5), 890–892.
- Poquet, E., Dibiane, A., Jourdain, C., el-Amine, M., Jacob, A., & Escure, M. N. (1995). Blunt injury of the larynx by hanging. X-ray computed tomographic aspect. [Traumatisme ferme du larynx par pendaison. Aspect scanographique a propos d'un cas] *Journal De Radiologie*, 76(2–3), 107–109.
- Porr, J., Laframboise, M., & Kazemi, M. (2012). Traumatic hyoid bone fracture—a case report and review of the literature. *The Journal of the Canadian Chiropractic Association*, 56(4), 269.
- Porzionato, A., Macchi, V., Rodriguez, D., & De Caro, R. (2007). Airway obstruction by laryngeal masses in sudden and homicidal deaths. *Forensic Science International*, 171(1), e15–e20.
- Pritchard, A. J., Reckdenwald, A., & Nordham, C. (2015, December 30). Nonfatal strangulation as part of domestic violence: A review of research. *Trauma, Violence & Abuse*. doi: 10.1177/1524838015622439.
- Purvin, V. (1997). Unilateral Headache and Ptosis in a 30-Year-Old Woman. *Survey of Ophthalmology*, 42(2), 163–168.
- Putaala, J., Kurkinen, M., Tarvos, V., Salonen, O., Kaste, M., & Tatlisumak, T. (2009). Silent brain infarcts and leukoaraiosis in young adults with first-ever ischemic stroke. *Neurology*, 72(21), 1823–1829.
- Putaala, J., Metso, A. J., Metso, T. M., Konkola, N., Kraemer, Y., Haapaniemi, E., & Tatlisumak, T. (2009). Analysis of 1008 consecutive patients aged 15 to 49 with first-ever ischemic stroke: The Helsinki young stroke registry. *Stroke; a Journal of Cerebral Circulation*, 40(4), 1195–1203.
- Ramirez, J. I., Petrone, P., Kuncir, E. J., & Asensio, J. A. (2004). Thyroid storm induced by strangulation. *Southern Medical Journal*, 97(6), 608–610.
- Rasmussen, E. R., Larsen, P. L., Andersen, K., Larsen, M., Qvortrup, K., & Hougen, H. P. (2013). Petechial hemorrhages of the tympanic membrane in attempted suicide by hanging: A case report. *Journal of Forensic and Legal Medicine*, 20(2), 119–121.
- Re, L., Birkhoff, J. M., Sozzi, M., Andrello, L., & Osculati, A. M. (2015). The choking game: A deadly game. Analysis of two cases of “self-strangulation” in young boys and review of the literature. *Journal of Forensic and Legal Medicine*, 30, 29–33.
- Reid, L. A., Dunn, M., Mckeown, D. W., & Oglesby, A. J. (2011). Surgical airway in emergency department intubation. *European Journal of Emergency Medicine: Official Journal of the European Society for Emergency Medicine*, 18(3), 168–171.
- Richards, C. E., & Wallis, D. N. (2005). Asphyxiation: A review. *Trauma*, 7(1), 37–45.
- Robison, D., & Hunt, S. (2005). Sudden In-custody death syndrome. *Advanced Emergency Nursing Journal*, 27(1), 36–43.
- Rozycki, H. J., Van Houten, M. L., & Elliott, G. R. (1996). Quantitative assessment of intrathoracic airway collapse in infants and children with tracheobronchomalacia. *Pediatric Pulmonology*, 21(4), 241–245.

- Saha, A., Bansal, A., & Kaur, S. (2010). Post obstructive pulmonary edema following accidental strangulation. *Indian Journal of Pediatrics*, 77(5), 584–584.
- Sauvageau, A., & Boghossian, E. (2010). Classification of asphyxia: The need for standardization. *Journal of Forensic Sciences*, 55(5), 1259–1267.
- Sauvageau, A., & Racette, S. (2006). Autoerotic deaths in the literature from 1954 to 2004: A review. *Journal of Forensic Sciences*, 51(1), 140–146.
- Sauvageau, A., Ambrosi, C., & Kelly, S. (2012). Autoerotic nonlethal filmed hangings: A case series and comments on the estimation of the time to irreversibility in hanging. *The American Journal of Forensic Medicine and Pathology*, 33(2), 159–162.
- Sauvageau, A., & Yesovitch, R. (2006). Choking on toilet paper: An unusual case of suicide and a review of the literature on suicide by smothering, strangulation, and choking. *The American Journal of Forensic Medicine and Pathology*, 27(2), 173–174.
- Schmidt, P., & Madea, B. (1995). Homicide in the bathtub. *Forensic Science International*, 72(2), 135–146.
- Schroeder, U., Motzko, M., Wittekindt, C., & Eckel, H. (2003). Hoarseness after laryngeal blunt trauma: A differential diagnosis between an injury to the external branch of the superior laryngeal nerve and an arytenoid subluxation. A case report and literature review. *European Archives of Oto-Rhino-Laryngology*, 260(6), 304–307.
- Sep, D., & Thies, K. (2007). Strangulation injuries in children. *Resuscitation*, 74(2), 386–391.
- Sethi, P. K., Sethi, N. K., Torgovnick, J., & Arsur, E. (2012). Delayed left anterior and middle cerebral artery hemorrhagic infarctions after attempted strangulation: A case report. *The American Journal of Forensic Medicine and Pathology*, 33(1), 105–106.
- Sharma, B., Harish, D., Sharma, A., Sharma, S., & Singh, H. (2008). Injuries to neck structures in deaths due to constriction of neck, with a special reference to hanging. *Journal of Forensic and Legal Medicine*, 15(5), 298–305.
- Sheridan, D. J., & Nash, K. R. (2007). Acute injury patterns of intimate partner violence victims. *Trauma, Violence & Abuse*, 8(3), 281–289.
- Shetty, U., Deepak, M., Hussain, S. A., Usmani, H., Osama, M., Pereira, K. G., & Menezes, R. G. (2016). Survival following accidental scarf strangulation. *The Medico-Legal Journal*, 84(3), 150–152. doi: 10.1177/0025817216643443.
- Shields, L. B., Hunsaker, D. M., & Hunsaker, J. C., III. (2005). Autoerotic asphyxia: Part I. *The American Journal of Forensic Medicine and Pathology*, 26(1), 45–52.
- Shields, L. B., Hunsaker, D. M., Hunsaker, J. C., III., Wetli, C. V., Hutchins, K. D., & Holmes, R. M. (2005). Atypical autoerotic death: Part II. *The American Journal of Forensic Medicine and Pathology*, 26(1), 53–62.
- Shields, L. B., Corey, T. S., Weakley-Jones, B., & Stewart, D. (2010). Living victims of strangulation: A 10-year review of cases in a metropolitan community. *The American Journal of Forensic Medicine and Pathology*, 31(4), 320–325.
- Shumaker, D., Kottamasu, S., Preston, G., & Treloar, D. (1988). Acute pulmonary edema after near strangulation. *Pediatric Radiology*, 19(1), 59–60.

- Singh, B., Kumar, S., & Kumar, V. (2003). Blunt laryngotracheal injury following accidental strangulation. *Injury, 34*(12), 937–939.
- Smith, D. J., Jr., Mills, T., & Taliaferro, E. H. (2001). Frequency and relationship of reported symptomology in victims of intimate partner violence: The effect of multiple strangulation attacks. *The Journal of Emergency Medicine, 21*(3), 323–329.
- Snider, C., Webster, D., O'Sullivan, C. S., & Campbell, J. (2009). Intimate partner violence: Development of a brief risk assessment for the emergency department. *Academic Emergency Medicine, 16*(11), 1208–1216.
- Sorenson, S. B., Joshi, M., & Sivitz, E. (2014). A systematic review of the epidemiology of nonfatal strangulation. A human rights and health concern. *American Journal of Public Health, 104*(11), e54–e61.
- Stanley, R. B., & Hanson, D. G. (1983). Manual strangulation injuries of the larynx. *Archives of Otolaryngology, 109*(5), 344–347.
- Stapczynski, J. S. (2010). Strangulation injuries. *Emergency Medicine Reports, 31*(17), 193–203.
- Stark, P., & Stark, H. E. (2010). Pulmonary manifestations of trauma. *Contemporary Diagnostic Radiology, 33*(16), 1–6.
- Stewart, D. E., Gagnon, A. J., Merry, L. A., & Dennis, C. (2012). Risk factors and health profiles of recent migrant women who experienced violence associated with pregnancy. *Journal of Women's Health, 21*(10), 1100–1106.
- Strack, G. B., & Gwinn, C. (2011). On the edge of homicide: Strangulation as a prelude. *Criminal Justice, 26*, 32.
- Strack, G. B., & McClane, G. (1999). *How to improve your investigation and prosecution of strangulation cases* (2nd ed.). D. C. James. (Ed.). San Diego, CA. Retrieved May 5, 2016, from [http://www.ncdsv.org/images/strangulation\\_article.pdf](http://www.ncdsv.org/images/strangulation_article.pdf)
- Strack, G. B., McClane, G. E., & Hawley, D. (2001). A review of 300 attempted strangulation cases. Part I: Criminal legal issues. *The Journal of Emergency Medicine, 21*(3), 303–309.
- Sugar, N., Fine, D., & Eckert, L. (2004). Physical injury after sexual assault: Findings of a large case series. *American Journal of Obstetrics and Gynecology, 190*(1), 71–76.
- Tabata, N. (1998). Morphological changes in traumatized skeletal muscle: The appearance of opaque fibers of cervical muscles as evidence of compression to the neck. *Forensic Science International, 96*(2), 197–214.
- Taliaferro, E., Hawley, D., McClane, G., & Strack, G. (2009). Strangulation in intimate partner violence. In C. Mitchell & D. Anglin (Eds.), *Intimate partner violence: A health-based perspective* (pp. 217-236). New York, NY: Oxford University Press.
- Taliaferro, E., Mills, T., & Walker, S. (2001). Walking and talking victims of strangulation. Is there a new epidemic? A commentary. *The Journal of Emergency Medicine, 21*(3), 293–295.
- Taniguchi, T., Saito, S., Mizukoshi, Y., Goto, Y., & Inaba, H. (2002). Multiple organ failure after strangulation

- injury. *Intensive Care Medicine*, 28(8), 1193.
- Taslimi, R., Daneshbod, Y., & Mirfazaelian, H. (2013). Facial petechia as a sign of strangulation in trauma victims. *Emergency Medicine Journal: EMJ*, 30(4), 311.
- Taussig, L. M., Cota, K., & Kaltenborn, W. (1981). Different mechanical properties of the lung in boys and girls 1–4. *American Review of Respiratory Disease*, 123(6), 640–643.
- Thomas, J. A., Ware, T. M., & Counselman, F. L. (2002). Internal carotid artery pseudo aneurysm masquerading as a peritonsillar abscess. *The Journal of Emergency Medicine*, 22(3), 257–261.
- Thomas, K. A., Joshi, M., & Sorenson, S. B. (2014). “Do you know what it feels like to drown?” Strangulation as coercive control in intimate relationships. *Psychology of Women Quarterly*, 38, 124–137.
- Toblin, R. L., Paulozzi, L. J., Gilchrist, J., & Russell, P. J. (2008). Unintentional strangulation deaths from the “choking game” among youths aged 6–19 years—United States, 1995–2007. *Journal of Safety Research*, 39(4), 445–448.
- Tough, S. C., Butt, J. C., & Sanders, G. L. (1994). Autoerotic asphyxial deaths: Analysis of nineteen fatalities in Alberta, 1978 to 1989. *The Canadian Journal of Psychiatry/La Revue Canadienne De Psychiatrie*, 39(3), 157–160.
- Tournel, G., Hubert, N., Rougé, C., Hédouin, V., & Gosset, D. (2001). Complete autoerotic asphyxiation: Suicide or accident? *The American Journal of Forensic Medicine and Pathology*, 22(2), 180–183.
- Trevillion, K., Agnew-Davies, R., & Howard, L. M. (2013). Healthcare professionals’ response to domestic violence. *Primary Health Care*, 23(9), 34–42.
- Turillazzi, E., D’Errico, S., Neri, M., & Fineschi, V. (2006). An unusual mechanical asphyxia in a homicide-suicide case by smothering and strangulation. *The American Journal of Forensic Medicine and Pathology*, 27(2), 166–168.
- Turkel, A. (2007). “And then he choked me.” *Understanding and Investigation Strangulation. Update: American Prosecutor’s Research Institute*, 20, 1–2.
- Ullrich, N. J., & Goodkin, H. P. (2015, June 30). The “choking game” and other strangulation activities in children and adolescents. *UptoDate*. Retrieved May 11, 2016, from <http://www.uptodate.com/contents/inherited-susceptibility-to-breast-and-ovarian-cancer-next-generation-sequencing-panels/abstract/103>
- Vanezis, P., Claydon, S., M. Chapman, R. C., & al-Alousi, L. M. (1993). Internal carotid artery thrombosis following manual strangulation. *Medicine, Science, and the Law*, 33(1), 69–71.
- Verma, S. (2007). Pediatric and adolescent strangulation deaths. *Journal of Forensic and Legal Medicine*, 14(2), 61–64.
- Vilke, G. M., & Chan, T. C. (2011). Evaluation and management for carotid dissection in patients presenting after choking or strangulation. *The Journal of Emergency Medicine*, 40(3), 355–358.
- Wahlen, B. M., & Thierbach, A. R. (2002). Near-hanging. *European Journal of Emergency Medicine*, 9(4), 348–350.

- Wailoo, M. P., & Emery, J. L. (1982). Normal growth and development of the trachea. *Thorax*, 37(8), 584–587.
- Walsh, F. M., Stahl, C. J., III, Unger, H. T., Lilienstern, O. C., & Stephens, R. G., III. (1977). Autoerotic asphyxial deaths: A medicolegal analysis of forty-three cases. *Legal Medicine Annual*, 155–182.
- Wang, Q., Ishikawa, T., Michiue, T., Zhu, B., Guan, D., & Maeda, H. (2012). Intrapulmonary aquaporin-5 expression as a possible biomarker for discriminating smothering and choking from sudden cardiac death: A pilot study. *Forensic Science International*, 220(1), 154–157.
- Wang, W., Kong, L., Dong, R., & Zhao, H. (2007). Fracture of the hyoid bone associated with atlantoaxial subluxation: A case report and review of the literature. *The American Journal of Forensic Medicine and Pathology*, 28(4), 345–347.
- Wehner, F., Martin, D. D., & Wehner, H. (2004). Asphyxia due to pacifiers—Case report and review of the literature. *Forensic Science International*, 141(2), 73–75.
- Wheeler, A., New York State Division of Criminal Justice Services, Office of Justice Research & Performance. (2012). *Arrests and arraignments involving strangulation offenses Nov. 11, 2010–June 30, 2012*. Albany, NY: NY State Division of Criminal Justice Services. Retrieved May 6, 2016, from <http://www.criminaljustice.ny.gov/pio/research-update-strangulation-apr2012.pdf>
- White, J. K., & Carver, J. (2012). Self-induced vomiting as a probable mechanism of an isolated hyoid bone fracture. *The American Journal of Forensic Medicine and Pathology*, 33(2), 170–172.
- Wiegand, P., & Kleiber, M. (1997). DNA typing of epithelial cells after strangulation. *International Journal of Legal Medicine*, 110(4), 181–183.
- Wilbur, L., Higley, M., Hatfield, J., Surprenant, Z., Taliaferro, E., Smith, D. J., & Paolo, A. (2001). Survey results of women who have been strangled while in an abusive relationship. *The Journal of Emergency Medicine*, 21(3), 297–302.
- Wilson, J. S., West, J. F., Messing, J. T., Brown, S., Patchell, B., & Campbell, J. C. (2011). Factors related to posttraumatic stress symptoms in women experiencing police-involved intimate partner violence. *Advances in Nursing Science*, 34(3), E14–E28.
- Wu, M., Tsai, Y., Lin, M., Hsu, I., & Fong, Y. (2004). Complete laryngotracheal disruption caused by blunt injury. *The Annals of Thoracic Surgery*, 77(4), 1211–1215.
- Yacobi, Y., Tsivian, A., & Sidi, A. A. (2007). Emergent and surgical interventions for injuries associated with eroticism: A review. *The Journal of Trauma*, 62(6), 1522–1530.
- Yen, K., Thali, M. J., Aghayev, E., Jackowski, C., Schweitzer, W., Boesch, C., & Sonnenschein, M. (2005). Strangulation signs: Initial correlation of MRI, MSCT, and forensic neck findings. *Journal of Magnetic Resonance Imaging*, 22(4), 501–510.
- Yen, K., Vock, P., Christe, A., Scheurer, E., Plattner, T., Schön, C., & Thali, M. J. (2007). Clinical forensic radiology in strangulation victims: Forensic expertise based on magnetic resonance imaging (MRI) findings. *International Journal of Legal Medicine*, 121(2), 115–123.